J Obstet Gynecol Cancer Res. 2017 November; 2(4):e63858. doi: 10.5812/jogcr.63858.

Published online 2017 November 26. **Case Report**

Retroperitoneal Lymphocele in a Patient with Primary Ovarian Cancer: A Case Report

Leila Mousavi Seresht,[1] Meysam Izadi,[2] Zohreh Yousefi,[1,*] Amir Hosein Jafarian,[3] Nooshin Babapour,[1] Laya Shirinzadeh,[1] and Zahra Rastin[1]

[1]Department of Obstetrics and Gynecology, Faculty of Medicine, Mashhad University of Medical Sciences, Mashhad, Iran
[2]Department of Radiology, Faculty of Medicine, Mashhad University of Medical Sciences, Mashhad, Iran
[3]Department of Pathology, Faculty of Medicine, Mashhad University of Medical Sciences, Mashhad, Iran

[*]*Corresponding author*: Dr Zohreh Yousefi, Professor, Department of Obstetrics and Gynecology, Faculty of Medicine, Mashhad University of Medical Sciences, Mashhad, Iran. E-mail: yousefiz@mums.ac.ir

Received 2017 October 18; **Accepted** 2017 November 12.

Abstract

Introduction: In patients with female genital tract cancers, during treatment, differentiating between a tumor recurrence and a benign phenomenon is of great importance. This study aimed to report a case of retroperitoneal lymphocele in a patient with primary ovarian cancer.
Case Presentation: A 49-year-old woman diagnosed with papillary serous ovarian carcinoma was referred to the oncology clinic in 2017. She was treated with an optimal surgical staging and underwent adjuvant chemotherapy. After 3 courses of chemotherapy, she complained of a large abdominal mass in the umbilical area. Evaluating the mass confirmed retroperitoneal lymphocele, which was treated with a non-surgical therapy.
Conclusions: Pelvic mass in patients with previous ovarian cancer is not necessarily due to the recurrence of the tumor and the possibility of lymphocele diagnosis should be considered. Since preventing the causes of lymphocele is very difficult, it is only necessary to carefully follow-up and provide essential consultations for high-risk patients.

Keywords: Retroperitoneal Lymphocele, Primary Ovarian Cancer, Cancer Surgical Staging, Chemotherapy

1. Introduction

Lymphocele is a complication of radical pelvic surgeries that include pelvic lymphadenectomy. It was first reported by Ferguson in 1961 as a liquid accumulation in the retroperitoneal space at the site of a surgery, which can be regarded as a potential space between muscles in the abdomen and the peritoneum, by injecting contrast agents into lymphatic vessels. In most patients, this space fades away spontaneously (1). Since removing the pelvic and para-aortic lymph nodes plays an important role in increasing the overall survival and disease-free survival of patients with genital cancers, especially ovarian and peritoneal cancer, the likelihood of retroperitoneal lymphocele, known as a complication of this type of surgery, should be considered (2). The incidence of this complication increases the length of hospitalization, prolongs courses of chemotherapy, and then affects the quality of life among patients. Nearly 35% of ovarian surgeries may lead to such a complication. The prevalence of this complication is reported to be between 16% and 60%. There is a disagreement on the prevalence of this phenomenon among various cancers of the female genital tract. However, it is reported that ovarian cancer is the most common type of cancer, which underlies this complication (3). Retroperitoneal lymphocele usually occurs within 1 to 17 months after an initial surgery, is usually asymptomatic, and leads to spontaneous recovery in a few months. In addition, lymphocele was even reported 18 years after having a surgery. Several methods have been proposed for the treatment of retroperitoneal lymphocele including applying sclerosing agents (4). In a report, after treating 120 patients with a 60-month follow-up, removal of lesion with laparoscopic surgery, which is associated with a lower recurrence rate, was mentioned as the first line of treatment of symptomatic lymphocele (5). The present study aimed to report a case of retroperitoneal lymphocele in a patient with primary ovarian cancer.

2. Case Presentation

A 49-year-old woman with a history of 5 pregnancies was initially referred to the Oncology clinic in 2017 of an academic hospital, Mashhad University of Medical Sciences due to having abdominal pain, abnormal bleeding, and a pelvic mass in 2017. The patient underwent optimal staging surgery for primary ovarian cancer together with complete pelvic and para-aortic lymphadenectomy. Diagnosis of the pathology was stage $1c_{G2}$- papillary serous ovarian cancer. The initial CA125 marker was higher than 600 units. The patient underwent adjuvant chemotherapy with the paclitaxel and carboplatin regimen. After 3

courses of chemotherapy and before the 4th course, she complained of a large abdominal mass up the umbilical area. At the examination, a soft, mobile, and bulky mass, with dimensions of 20 to 18 cm, was found. Carrying out a sonography indicated that specifications of the mass were as follows: a cyst with a thin and delicate septum on the left side of the pelvis without nodule and a thick septum. A computed tomography (CT) scan reported the retroperitoneal cystic mass up to the top of the bladder (Figure 1). The CA125 marker was at a normal level. After a re-examination with a possibility of retroperitoneal lymphocele, by using the ultrasound-guided catheterization, evacuation and derange of cyst was performed a week after the catheter was removed. The patient, simultaneously with an antibiotic therapy, underwent the next course of chemotherapy. In the cytology sample with a preference for lymphocyte, 90% of abundant infiltrating cells were observed in each microscopic field (lymphocytosis) (Figure 2). A total of 2 weeks after the patient's treatment, a sonography was performed again, in which another cyst with dimensions of 5 to 6 cm was observed. This cyst was also catheterized and deranged. After the end of the course of chemotherapy, the patient was still asymptomatic at the 4-month follow-up and the level of the tumor marker and the sonography were normal.

Figure 1. CT Scan of the Retroperitoneal Cystic Mass Up to the Top of the Bladder

This report was conducted through obtaining the patient's full consent.

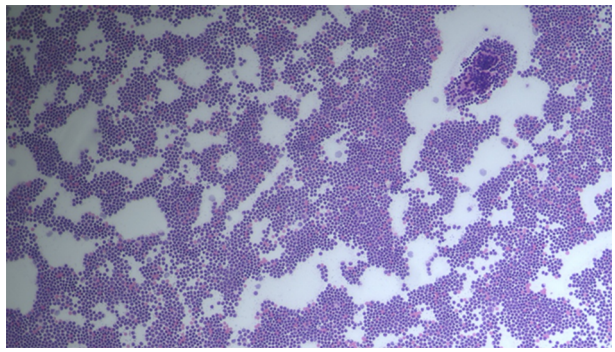

Figure 2. Cytology from Infiltrating 90% of Cells in Each Microscopic Field with a Preference for Lymphocele (Lymphocytosis)

3. Discussion

In this study, a case of retroperitoneal lymphocele was reported in the patient with primary ovarian cancer. This case was reported following a complete optimal surgery improved with a relatively non invasive treatment. Lymphocele is a complication that is followed by any radical surgery from prostate cancer and kidney transplantation to female genital tract cancers. It usually occurs asymptomatically and/or symptomatic as abdominal distension, illus, nausea and vomiting, pressure symptoms as a impaired mobility due to pressure on nerves, urinary obstruction, pyelonephritis, inflammation of the external genitalia and lower extremities, obstruction of sigmoid colon and pelvic thrombosis, shallows ascites, as well as psychological symptoms due to frequent hospitalizations (6). Ovarian cancer is the most common type of cancer that causes lymphocele. Since in advanced ovarian cancers, cytoreductive surgery has a high prognostic effect in increasing a patient's overall and disease-free survival, it naturally accompanies with more complications. The complication occurs between 1 and 17 months after an initial surgery and its symptomatic type indicates itself in 3 to 5 months. However, most of the subclinical cases improve spontaneously within several months (7). Among risk factors for the development of lymphocele, a body mass index (BMI) higher than 25, a broad lymphadenectomy (more than 27), metastatic lymph nodes, receiving heparin prophylaxis, lymphatic ligation failure, laparotomy versus laparoscopy, chemotherapy, and primary or secondary radiotherapy can be mentioned. Moreover, the role of the close retroperitoneal drainage, through justifying its effect in increasing the necrosis drainage, as an external object, was considered as a risk factor. This is while it was stated that if we used the technique, open vaginal cuff, and left open the peritoneum the risk can be reduced (8, 9).

The patient in this study underwent cytoreductive surgery, extensive pelvic and para-aortic lymphadenectomy, heparin prophylaxis, and placing drain for drainage. Additionally, the vaginal cuff and peritoneum were left open in the surgery. The differential diagnoses of retroperitoneal lymphocyte are seroma, hematoma, abscess, urinoma, and tumor recurrence. Imaging methods (ultrasound and CT scan) are of significant importance (10). Regarding the proposed treatment for lymphocele, initially, the tumor recurrence should be ruled out. Afterwards, the necessary treatment should be carried out. Conducting a laparotomy, for open lymphocele drainage, together with marsupialization of the wall of the cyst, is an appropriate surgical procedure; however, they must try not to remove the wall of the lesion with regard to the possibility of a massive hemorrhage from the large pelvic vessels. Also, repeated catheterization lymphocele were recommended. Performing a vaginal drainage, with sclerosing agents, such as ethanol, Iodine, bleomycin, tetracycline, doxycycline, and applying an antibiotic therapy has also been used. The responcerate has been reported to be 90% to 100%. The second line of the standard treatment in the absence of response to this method of surgery is laparoscopy drainage (11). In a study done on 102 symptomatic lymphocele patients, laparoscopy was initially performed for the treatment and a 60-month follow-up indicated that laparoscopy has been reported to be less recurrent with the advantage of detecting hideouts recurrences (5). Several methods proposed for preventing lymphocele include TachoSil® fibrin collagen patch used after pelvic lymphadenectomy or in the groin after the surgery and FLOSEAL, a set of gelatin, thrombin, ligaclips, and ultracision, which in comparison with bipolar electrosurgical cauterization has been more effective in reducing the likelihood of this complication, although no definitive method has yet been presented (12). In relation to the impact of lymphatic complication on the survival rate of patients, a study conducted on 194 patients could not find any significant differences and just the fear of postponing chemotherapy was mentioned (13).

3.1. Conclusion

Having a pelvic mass in patients with ovarian cancer is not necessarily due to the recurrence of the tumor and the possibility of lymphocele diagnosis should be considered. Since preventing the causes of lymphocele is very difficult, it is only necessary to carefully follow-up and provide essential consultations to high-risk patients.

References

1. Zikan M, Fischerova D, Pinkavova I, Slama J, Weinberger V, Dusek L, et al. A prospective study examining the incidence of asymptomatic and symptomatic lymphoceles following lymphadenectomy in patients with gynecological cancer. *Gynecol Oncol*. 2015;**137**(2):291–8. doi: 10.1016/j.ygyno.2015.02.016. [PubMed: 25720294].
2. Minig L, Patrono MG, Cardenas-Rebollo JM, Martin Marfil P, Rodriguez-Tabares V, Chuang L. Use of TachoSil(R) to Prevent Symptomatic Lymphocele after an Aggressive Tumor Debulking with Lymphadenectomy for Advanced Stage Ovarian Cancer. A Pilot Study. *Gynecol Obstet Invest*. 2016;**81**(6):497–503. doi: 10.1159/000443640. [PubMed: 27046053].
3. Pastore M, Manci N, Marchetti C, Esposito F, Iuliano M, Manganaro L, et al. Late aortic lymphocele and residual ovary syndrome after gynecological surgery. *World J Surg Oncol*. 2007;**5**:146. doi: 10.1186/1477-7819-5-146. [PubMed: 18163910].
4. Gauthier T, Uzan C, Lefeuvre D, Kane A, Canlorbe G, Deschamps F, et al. Lymphocele and ovarian cancer: risk factors and impact on survival. *Oncologist*. 2012;**17**(9):1198–203. doi: 10.1634/theoncologist.2012-0088. [PubMed: 22707515].
5. Radosa MP, Diebolder H, Camara O, Mothes A, Anschuetz J, Runnebaum IB. Laparoscopic lymphocele fenestration in gynaecological cancer patients after retroperitoneal lymph node dissection as a first-line treatment option. *BJOG*. 2013;**120**(5):628–36. doi: 10.1111/1471-0528.12103. [PubMed: 23320834].
6. Goes Junior AM, Jeha SA. Idiopathic lymphocele: a possible diagnosis for infraclavicular masses. *Case Rep Surg*. 2012;**2012**:593028. doi: 10.1155/2012/593028. [PubMed: 23008796].
7. Buda A, Ghelardi A, Fruscio R, Guelfi F, La Manna M, Dell'Orto F, et al. The contribution of a collagen-fibrin patch (Tachosil) to prevent the postoperative lymphatic complications after groin lymphadenectomy: a double institution observational study. *Eur J Obstet Gynecol Reprod Biol*. 2016;**197**:156–8. doi: 10.1016/j.ejogrb.2015.12.005. [PubMed: 26765122].
8. Tinelli A, Mynbaev OA, Tsin DA, Giorda G, Malvasi A, Guido M, et al. Lymphocele prevention after pelvic laparoscopic lymphadenectomy by a collagen patch coated with human coagulation factors: a matched case-control study. *Int J Gynecol Cancer*. 2013;**23**(5):956–63. doi: 10.1097/IGC.0b013e31828eeea4. [PubMed: 23574881].
9. Achouri A, Huchon C, Bats AS, Bensaid C, Nos C, Lecuru F. Complications of lymphadenectomy for gynecologic cancer. *Eur J Surg Oncol*. 2013;**39**(1):81–6. doi: 10.1016/j.ejso.2012.10.011. [PubMed: 23117018].
10. Kim HY, Kim JW, Kim SH, Kim YT, Kim JH. An analysis of the risk factors and management of lymphocele after pelvic lymphadenectomy in patients with gynecologic malignancies. *Cancer Res Treat*. 2004;**36**(6):377–83. doi: 10.4143/crt.2004.36.6.377. [PubMed: 20368832].
11. Kohler C, Kyeyamwa S, Marnitz S, Tsunoda A, Vercelino F, Schneider A, et al. Prevention of lymphoceles using FloSeal and CoSeal after laparoscopic lymphadenectomy in patients with gynecologic malignancies. *J Minim Invasive Gynecol*. 2015;**22**(3):451–5. doi: 10.1016/j.jmig.2014.12.007. [PubMed: 25499774].
12. Buda A, Fruscio R, Pirovano C, Signorelli M, Betti M, Milani R. The use of TachoSil for the prevention of postoperative complications after groin dissection in cases of gynecologic malignancy. *Int J Gynaecol Obstet*. 2012;**117**(3):217–9. doi: 10.1016/j.ijgo.2011.12.021. [PubMed: 22424660].
13. Gallotta V, Fanfani F, Rossitto C, Vizzielli G, Testa A, Scambia G, et al. A randomized study comparing the use of the Ligaclip with bipolar energy to prevent lymphocele during laparoscopic pelvic lymphadenectomy for gynecologic cancer. *Am J Obstet Gynecol*. 2010;**203**(5):483. doi: 10.1016/j.ajog.2010.06.053. [PubMed: 20723873].