


Diagnosis and Management of COVID-19 in the Third Trimester of Pregnancy: A Case Report

Arash Moshiri¹, Maryam Ahmadian², Seyedeh Nafiseh Naseri³, Shima Sheibani⁴,
Mahboobeh Shirazi^{5*} , Baratoallah Akbari⁶, Atefeh Hoseinzadeh⁶

1. Internist, Mostafa Khomeini Hospital, Birjand University of Medical Sciences, Tabas, Iran
2. Obstetrician, Besat Nahaja General Hospital, Tehran, Iran
3. Emergency Medicine Specialist, Mostafa Khomeini Hospital, Birjand University of Medical Sciences, Tabas, Iran
4. Emergency Medicine Specialist, Mostafa Khomeini Hospital, Birjand University of Medical Sciences, Tabas, Iran
5. Associate Professor, Department of Perinatology, Yas Women Hospital, Tehran University of Medical Sciences, Tehran, Iran
6. Nurse, Mostafa Khomeini Hospital, Birjand University of Medical Sciences, Tabas, Iran

Article Info

 [10.30699/jogcr.5.2.49](https://doi.org/10.30699/jogcr.5.2.49)

Received: 2020/07/21;
Accepted: 2020/07/28;
Published Online: 30 Oct 2020;

Use your device to scan and read the article online



ABSTRACT

Background & Objective: In this present study, we reported a 31-week pregnant woman who had a history of fever and chills in the past two days referred to Mostafa Khomeini Hospital in Tabas.

Case Report: A 29-year-old pregnant woman with a gestational age of 31 weeks presented to the gynecology clinic. Her chief complaint was a history of fever and chills in the recent past two days. Since there were no suspicious findings in favor of infections, related to obstetrics and gynecology, the patient was referred to Mostafa Khomeini Hospital in Tabas (June 2020). The initial clinical examination revealed no fever, chills, cough, respiratory distress, body aches, gastrointestinal problems or anything else. The patient's oxygen saturation level was 98%. Routine laboratory tests were requested for the patient. WBC count was 14000, lymphocyte count was 875 (6.25%), and platelet count was 117000. According to the recent history of clinical symptoms and positive paraclinical results, COVID-19 was suspected. In the chest CT findings, bilateral ground glass opacities (GGO) and consolidations were observed, which were compatible with COVID-19 pattern. Based on the positive clinical and lab tests, COVID-19 was detected and positive RT-PCR COVID-19 test confirmed our diagnosis.

Conclusion: The patient was asymptomatic at the time of admission to our ward; however, she reported fever and chills in the last two days, which raised our suspicion about COVID-19. Due to significant lymphopenia and the increase in granulocytes counts, and thrombocytopenia accompanied with complementary lab tests, severe COVID-19 was diagnosed and confirmed with positive RT-PCR test.

Keywords: COVID-19; Fever; Chills, Leukocytosis, Lymphopenia, Pregnancy

Corresponding Information:

Mahboobeh Shirazi, Associate Professor, Department of Perinatology, Yas Women Hospital, Tehran University of Medical Sciences, Tehran, Iran. Email: mahboobehshirazi4@gmail.com Tel: +98 21 66591316



Copyright © 2020, This is an original open-access article distributed under the terms of the Creative Commons Attribution-noncommercial 4.0 International License which permits copy and redistribution of the material just in noncommercial usages with proper citation.

Introduction

COVID-19 is an infectious, acute, highly contagious, and multi-organ disease, which was first reported in Wuhan, China, in December 2019. Nowadays, this disease has been announced as a global public health emergency by the World Health Organization (1-3).

The clinical symptoms of COVID-19 vary from a mild flu-like manifestation to pneumonia, acute lung injury (ALI), acute respiratory distress syndrome (ARDS), or any organ involvement (2). Its main symptoms are fever and cough, with a frequency of 80%. The COVID-19 signs and symptoms during pregnancy are similar to those in normal and non-

pregnant people (1). Previous studies have indicated that immunological and physiological changes in pregnancy may put a pregnant woman at a higher risk for COVID-19 (2, 4). Although no evidence has been found to support the vertical transmission of the virus during pregnancy (5), many cases of perinatal mortality and morbidity have been reported. A study performed in Iran has demonstrated that in 30 days, of nine pregnant patients hospitalized due to COVID-19, seven patients died, and one patient had severe condition and underwent a mechanical ventilation (6). A mortality due to COVID-19 has also been reported in the UK. The patient was a 29-year-old diabetic

pregnant woman who died of pulmonary embolism and cerebral basilar artery thrombosis (7). Another study figured out that despite lack of findings in favor of vertical transmission, the prevalence of preterm labor (41.1%) and perinatal death (7%) due to COVID-19 was significant (8). A study conducted in China found that although PCR tests on the pharyngeal samples of nine infants born to mothers with COVID-19 were negative, the incidence of preterm labor, small for gestational age, and large for gestational age were 6, 2 and 1 infant(s), respectively (9).

The diagnosis of this disease is made based on epidemiological history, clinical manifestations, chest radiographic findings, and lab tests. Its treatment is mainly dependent on enough oxygen delivery, antiviral therapy, thromboembolic prophylaxis therapy, and supportive therapies. Interferon-alpha (IFN-beta one), remdesivir, and Hydroxychloroquine and ectara among the medications used to treat COVID-19 during pregnancy (10, 11).

In the present study, we reported the follow-up of a 31-week pregnant woman with a previous history of fever and chills in the past two days who referred to Mostafa Khomeini Hospital in Tabas.

Case Report

A 29-year-old pregnant woman with a gestational age of 31 weeks (Gravid 2, Para 1) with a history of preterm labor in her previous pregnancy (36 weeks), non-diabetic, and with a BMI = 22.5 Kg/m² referred to the gynecology clinic. The patient's main complaint was a history of fever and chills in the past two days. Since there were no suspicious findings in favor of chorioamnionitis, urinary tract infection, or other infections related to obstetrics and gynecology, the patient was referred to Mostafa Khomeini Hospital in Tabas (affiliated to Birjand University of Medical Sciences) in June 2020. The initial clinical examination revealed no fever, chills, cough, respiratory distress, body aches, or gastrointestinal problems or anything else. The patient's oxygen saturation was 98%. Routine lab tests were requested for the patient. WBC (leukocyte) count was 14,000, lymphocyte count was 875 (6.25%), and platelet count was 117,000 (Table 1).

Table 1. The results of cell blood count (CBC)

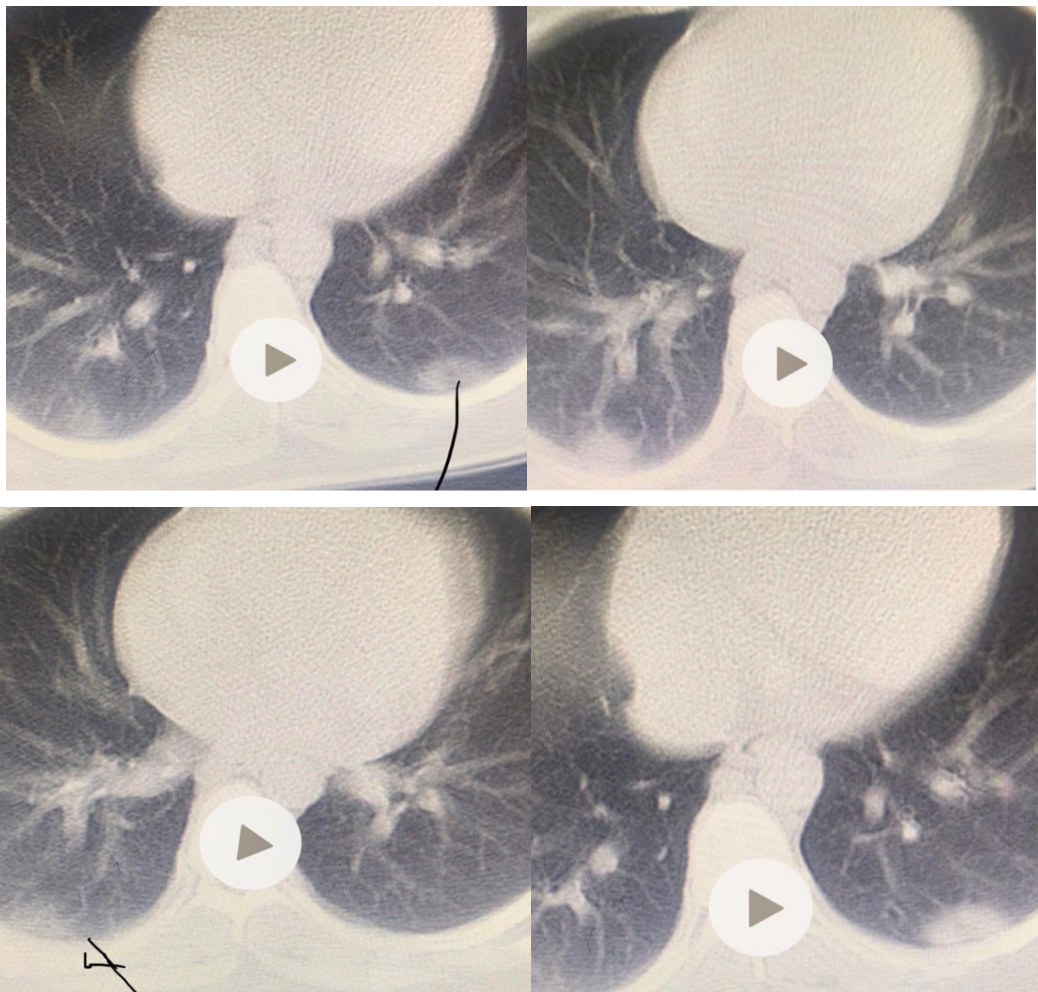
Hb (g/dL)	11.8
HCT (%)	33.4
Platelet (cells/mcL)	117000
MCV (fL)	80.7
WBC (cells/mcL)	14000
Granulocytes (cells/mcL)	89
Lymphocytes (cells/mcL)	875
Lymphocytes %	6.25

According to the history of clinical symptoms (fever and chills experienced in the past two days) and positive paraclinical tests (thrombocytopenia, increased PMN, and decreased lymphocytes), COVID-19 was suspected. For determining the disease severity, complementary tests were performed and a CT scan of the lung (using a shield) was requested. In CT findings, bilateral ground glass opacities (GGO Patterns) and consolidations were evident at the base of both lower lung zones, which were compatible with the COVID-19. Lung involvement was below 50% (Figures 1). A COVID-19 diagnostic test (RT-PCR) was requested. Based on the results of complementary tests (Table 2), liver and kidney function tests, as well as CPK Level

were normal endocarp was also negative; however, other factors such as LDH above of 245(323 U/L), PT; 16, INR; 1.21, and lymphocyte percentage; 6.25 were indicative as the COVID severity (12). A positive PCR test confirmed the diagnosis of COVID-19. The patient was hospitalized due to leukocytosis accompanied by lymphopenia, severe COVID-19, and previous history of preterm labor. Since this medical center did not have access to ferritin and D-Dimer test kits in blood, these two factors were not measured. Additionally, because the Troponin-I level was not titrated in the hospital laboratory, this test was not requested (A qualitative report of this factor was not valuable in determining the disease severity).

Table 2. The results of laboratory blood tests

Blood test	
BUN (mg/Dl)	8
Creatinine (mg/mL)	0.8
AST(U/L)	16
ALT(U/L)	17
Alkaline Phosphates (IU/L)	299
LDH(U/L)	323
PT (seconds)	16
INR	1.21
PTT(seconds)	32
CRP (mg/L)	Negative
CPK (U/L)	125
ESR (mm/hr)	20
D-Dimer (ng/mL)	1550

**Figures 1.** The patient's CT scan images before initiating the treatment: Involvement of the bases of both lungs with ground-glass opacity and consolidation were evident

The patient was hospitalized after diagnosing the disease and its severity (severe COVID-19). Also, 5000 units of heparin was injected subcutaneously twice a day, and due to the disease severity, antiviral medications were started. On the first day, the patient received hydroxychloroquine at a dose of 400 mg (BD) and azithromycin at a dose of 500 mg (Stat). This regimen was then continued by 200 mg hydroxychloroquine (BD) and 250 mg azithromycin (BD) for 6 days.

By performing periodic blood tests, after 7 days of treatment, the levels of WBC (leukocyte), lymphocytes, and PMN percentage in the blood were reached to 6500, 30% and 67%, respectively. Furthermore, due to the history of preterm labor and the severity of COVID-19, a D-Dimer test was requested to a private laboratory

center. Administration of heparin until the pregnancy termination was continued due to high level of D-Dimer 1550 more than 1000.

Because the patient was in the third trimester and had a history of preterm labor, fetal and placental health were monitored weekly with a biophysical profile test. A CT scan of the lung was again requested for the patient four weeks after discontinuing antiviral treatment. The results of radiological tests were normal (Figure 2). Due to the patient's stable condition, she was referred to the gynecology ward to continue prenatal care. Complete monitoring of the patient during labor, delivery, and postpartum was strongly recommended to prevent other morbidity and mortality (12).

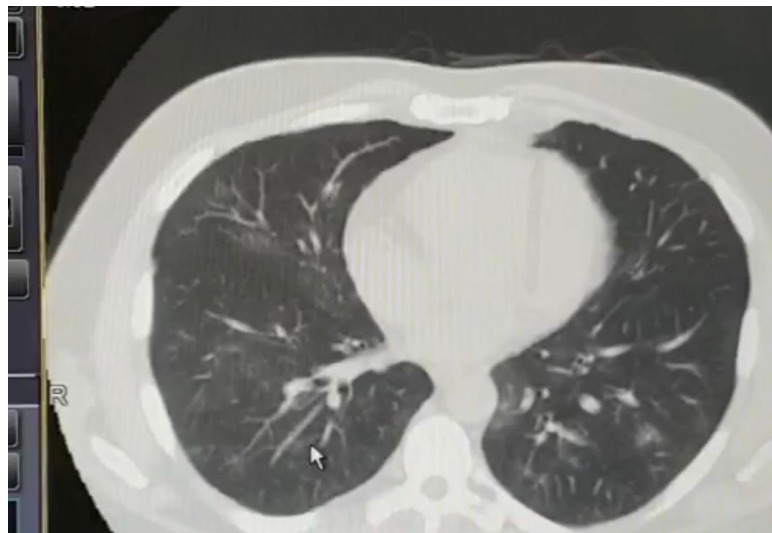

Figure 2. The patient's CT scan after seven days of the treatment with heparin and antiviral medications

Discussion

Our findings in this study showed that obtaining an accurate medical history of patient in combination with lab tests, especially lymphopenia and thrombocytopenia respectively are of paramount importance for COVID-19 diagnosis. The patient was asymptomatic at the time of presentation in to our ward. However, she reported fever and chills in the last two days, which raised our suspicion about the disease, so complementary blood tests were requested. Due to significant decrement in the percentage of lymphocytes from 30% to 6.25% and an incrementing granulocyte, the results of the initial blood tests conducted us for COVID-19 diagnosis. Considering the positive recent history of patient including fever and chills as well as paraclinical lab test findings, COVID-19 was diagnosed and chest CT scan was requested to determine the disease severity, CT findings demonstrated the bilateral lower lung zones involvement compatible with COVID-19. Additionally, the positive PCR test confirmed the diagnosis. Consistent with the findings of our study, in a review, Vakili *et al.* showed that although the laboratory findings in pregnant women with COVID-

19 were different and challenging, leukocytosis and increased neutrophil count, lymphopenia, and increased CRP and LDH were prevalent findings (13).

As there is no any correlation between COVID-19 diagnosis and chest CT involvement for diagnosing COVID severity, chest CT was requested. Samsami *et al.* reported a pattern of COVID-19 pneumonia on CT scan images of eight cases without respiratory symptoms. CT scans were conducted because these patients referred to the emergency ward and had a trauma (14).

Based on this patient's paraclinical Lab findings, the disease was severe. Although our patient was asymptomatic and non-diabetic, had a low body mass index (23 kg/m²; considering her being Asian), and had normal blood pressure, due to her gestational age of above 28 weeks, her preterm labor history, and the severity of COVID-19, a combination of azithromycin and hydroxychloroquine, as well as heparin, was started to prevent preterm labor and fetal demise. Because of a previous history of preterm labor, prevention of COVID-related thromboembolic problems, complications associated with uterine-

placental insufficiency, and the possibility of fetal death, heparin treatment was continued. Moreover, for performing prenatal care and observing safety protocols for transmitting the disease to others, a serial ultrasound was recommended until delivery to determine the fetal and placental health. In this regard, another study demonstrated that of 14 asymptomatic COVID-19 patients, 12 patients remained asymptomatic until the end of pregnancy and delivery and were only treated on an outpatient basis (14). Besides, since COVID-19 increases the risk of thromboembolic problems, the American Society of Hematology, the Urgent Medical Care Association, and the International Society on Thrombosis and Haemostasis suggested prophylactic treatment with anticoagulants (15).

Acknowledgments

This research was supported by Birjand University of Medical Sciences. We gratefully acknowledge the kind support of the participant for her precious collaboration in this study.

Conflict of Interest

Authors declared no conflict of interests.

References

- Rasmussen SA, Smulian JC, Lednický JA, Wen TS, Jamieson DJ. Coronavirus Disease 2019 (COVID-19) and pregnancy: what obstetricians need to know. *American Journal of Obstetrics & Gynecology*. 2020;222(5):415-26. [DOI:10.1016/j.ajog.2020.02.017] [PMID] [PMCID]
- Mardani M, Pourkaveh B. A Controversial Debate: Vertical Transmission of COVID-19 in Pregnancy. *Arch Clin Infect Dis*. 2020;15(1):e102286. [DOI:10.5812/archcid.102286]
- Chen H, Guo J, Wang C, Luo F, Yu X, Zhang W, et al. Clinical characteristics and intrauterine vertical transmission potential of COVID-19 infection in nine pregnant women: a retrospective review of medical records. *The Lancet*. 2020;395(10226):809-15. [DOI:10.1016/S0140-6736(20)30360-3]
- Qiao J. What are the risks of COVID-19 infection in pregnant women? *The Lancet*. 2020;395(10226):760-2. [DOI:10.1016/S0140-6736(20)30365-2]
- Coronavirus (COVID-19) infection and pregnancy UK: Royal College of Obstetricians and Gynaecologists; 2020 [Available from: <https://www.rcog.org.uk/coronavirus-pregnancy>].
- Hantoushzadeh S, Shamshirsaz AA, Aleyasin A, Seferovic MD, Aski SK, Arian SE, et al. Maternal death due to COVID-19. *American Journal of Obstetrics & Gynecology*. 2020;223(1):109.e1-.e16. [DOI:10.1016/j.ajog.2020.04.030] [PMID] [PMCID]
- Ahmed I, Azhar A, Eltaweel N, Tan BK. First COVID-19 maternal mortality in the UK associated with thrombotic complications. *British Journal of Hematology*. 2020;190(1):e37-e8. [DOI:10.1111/bjh.16849] [PMCID]
- Di Mascio D, Khalil A, Saccone G, Rizzo G, Buca D, Liberati M, et al. Outcome of coronavirus spectrum infections (SARS, MERS, COVID-19) during pregnancy: a systematic review and meta-analysis. *American Journal of Obstetrics & Gynecology MFM*. 2020;2(2). [DOI:10.1016/j.ajogmf.2020.100107] [PMID] [PMCID]
- Zhu H, Wang L, Fang C, Peng S, Zhang L, Chang G, et al. Clinical analysis of 10 neonates born to mothers with 2019-nCoV pneumonia. *Translational pediatrics*. 2020;9(1):51. [DOI:10.21037/tp.2020.02.06] [PMID] [PMCID]
- Mei Y, Luo D, Wei S, Liao X, Pan Y, Yang X, et al. Obstetric Management of COVID-19 in Pregnant Women. *Frontiers in Microbiology*. 2020;11(1186). [DOI:10.3389/fmicb.2020.01186] [PMID] [PMCID]
- Berghella V. Coronavirus disease 2019 (COVID-19): Pregnancy issues. *UpToDate Internet*. 2020.
- Sarani M, Shahraki Z, Shirazi M, Saravani S. Risk factors of maternal mortality in Sistan region: 10-year report. *Tehran University Medical Journal*. 2014;72(9):623-9.
- Vakili S, Savardashtaki A, Jamalnia S, Tabrizi R, Nematollahi MH, Jafarinaia M, et al. Laboratory Findings of COVID-19 Infection are Conflicting in Different Age Groups and Pregnant Women: A Literature Review. medRxiv. 2020:2020.04.24.20078568. [DOI:10.1101/2020.04.24.20078568]
- Samsami M, Bagherpour JZ, Nematihonar B, Tahmasbi H. COVID-19 pneumonia in asymptomatic trauma patients; report of 8 cases. *Archives of Academic Emergency Medicine*. 2020;8(1).
- Hirshberg JS, Stout MJ, Raghuraman N. Coronavirus disease 2019 infection among asymptomatic and symptomatic pregnant women: two weeks of confirmed presentations to an affiliated pair of New York City hospitals. *American Journal of Obstetrics & Gynecology Mfm*. 2020;2(3):100162. [DOI:10.1016/j.ajogmf.2020.100162] [PMID] [PMCID]

How to Cite This Article:

Moshiri A, Ahmadian M, Naseri S N, Sheibani S, Shirazi M, Akbari B et al . Diagnosis and Management of COVID-19 in the Third Trimester of Pregnancy: A Case Report. *J Obstet Gynecol Cancer Res*. 2020; 5 (2): 49-53