

A Mother with A Tumour Close To Her Heart: A Case Report on the Management of a Thymoma in Pregnancy

Yurkdes Aran Sittampalam^{1*} , Nicole AshaThayaparan², Narasimman Sathiamurthy¹,
Muniswaran Ganeshan²

1. Department of General Surgery, Hospital of Kuala Lumpur, Kuala Lumpur, Malaysia
2. Department of Obstetrics and Gynaecology, Women and Children's Hospital of Kuala Lumpur, Kuala Lumpur, Malaysia



Article Info

 [10.30699/jogcr.6.3.157](https://doi.org/10.30699/jogcr.6.3.157)

Received: 2020/10/17;

Accepted: 2021/02/24;

Published Online: 26 Jun. 2021

Use your device to scan and read the article online



Corresponding Information:

Yurkdes Aran Sittampalam,
Department of General Surgery, Hospital of
Kuala Lumpur, Kuala Lumpur, Malaysia
Email: yurkdes@gmail.com

ABSTRACT

Thymomas are seldom encountered in the general population, and even more-so uncommonly encountered in pregnancy. Patients usually present with either local, compressive symptoms such as shortness of breath or are asymptomatic and diagnosed incidentally on imaging studies. A subset of them may even present in association with myasthenia gravis. Management of pregnant patients with thymomas are challenging and require multi-disciplinary care involving thoracic surgeons, maternal-fetal medicine specialists, neonatologists and anaesthesiologists to facilitate safe progression of the pregnancy. We discuss the management of a patient that presented to us with a B2-type thymoma in pregnancy who successfully underwent a video-assisted thoracoscopic excision of the mass and went on to have a safe delivery. The optimal way forward in managing patients with thymomas in pregnancy would be through early recognition of the condition and instituting a multidisciplinary approach.

Keywords: Thymoma, B2-Type Thymoma, Video-assisted thoracoscopic surgery (VATS), Thoracic surgery, maternal fetal medicine



Copyright © 2021, This is an original open-access article distributed under the terms of the Creative Commons Attribution-noncommercial 4.0 International License which permits copy and redistribution of the material just in noncommercial usages with proper citation.

Introduction

Thymomas are seldom encountered in the general population, the incidence of which is approximately 0.13-0.15 per 100000 populations at risk (1). They are however the most common tumor encountered in the anterior mediastinum (2). In contrast, however thymomas encountered during pregnancy are very rare and there is no literature available on its incidence. Patients may present either with local symptoms such as an anterior mediastinal mass or shortness of breath, or they may be asymptomatic and are found incidentally on imaging (3). They may also be seen in association with myasthenia gravis (3). Presentation during pregnancy is clinically challenging thus, requiring a high index of clinical suspicion and once identified, in order for its management a multi-disciplinary approach between maternal fetal medicine specialists, thoracic surgeons, neurologists should be incorporated as well as anesthesiologists to ensure clearance of the disease and to facilitate safe progression of the pregnancy and ultimately delivery.

In this case report we discuss the management of a patient who referred to us with a B2-type Thymoma in pregnancy. She underwent a uniportal video-assisted thoracoscopic excision of her thymoma and subsequently continued her pregnancy to 38 weeks and successfully delivered via spontaneous vertex delivery.

Case Presentation

A 35-year-old woman presented to the emergency department with shortness of breath. After a thorough clinical examination, which was unremarkable, a chest radiograph was performed. It revealed a vague mediastinal mass, which then prompted a Computed Tomography (CT) scan of her Thorax. The CT Thorax reported a thymoma measuring 7x8x5cm (Figure 1). At this juncture, she was found to be 14 weeks pregnant. A CT-guided biopsy of the mass was taken and the sample confirmed a thymoma of the B2 subtype.

A multidisciplinary team meeting was held for her surgeons, obstetricians and other doctors involved in

her care following which a unanimous decision was made to proceed with surgery. She was also investigated for concurrent myasthenia gravis and was found to have ocular myasthenia gravis. Treatment with pyridostigmine was subsequently commenced.

She underwent a uniportal video-assisted thoracoscopic (VATS) thymectomy the following week at 15 weeks of gestation, which successfully removed the mass, measuring 8x7cm (Figure 2). She recovered well post-operatively without requiring intensive care support and was discharged within a week with confirmation of a viable fetus. Histopathological evaluation of the mass confirmed a B2-type thymoma, excised with clear margins. She had regular appointments with the maternal fetal medicine specialist, thoracic surgeon and the neurologist until she reached 38 weeks of gestation. She was then admitted for induction of labour for hypertension in pregnancy and went on to have a successful spontaneous vertex delivery.

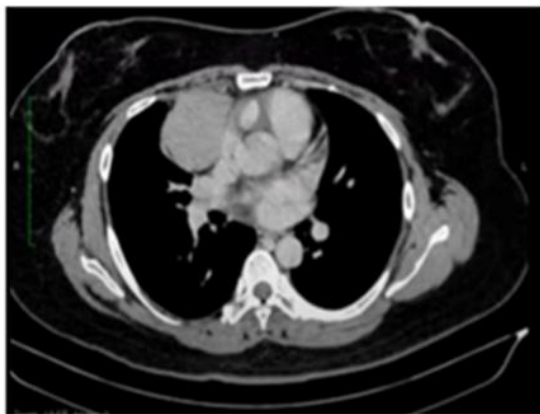


Figure 1. Spiral chest CT scan showing anterior mediastinal mass

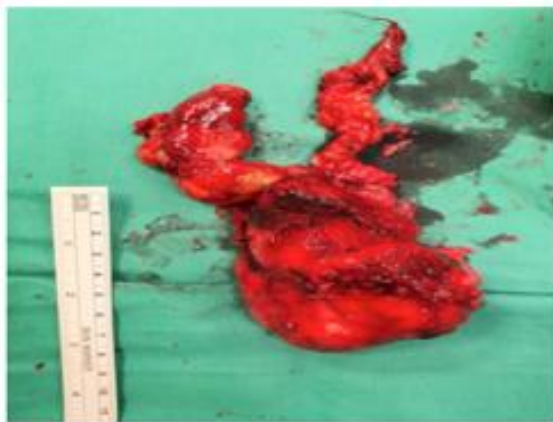

Figure 2. Surgical specimen

Discussion

Thymomas are uncommon pathologies and a high index of suspicion is usually required to clinch the diagnosis. Patients may present with localized pain, shortness of breath or superior vena cava syndrome (4). Symptoms of myasthenia gravis can be present in up to 50% of patients with thymomas, and up to 30% may be completely asymptomatic and are discovered to have thymomas on routine chest radiographs (5).

They are typically classified according to the World Health Organization (WHO) histologic classification that is based on their oncologic behavior (6). The types that have been defined are A and AB that can be typified as benign tumors, types B1 and B2 that are the borderline type bridging benign and malignant tumors, and types B3 and C that fall into the malignant end of the spectrum, C being thymic carcinoma (6). Another classification that is used is the Masaoka-Koga staging system (7).

Types A and AB thymomas have the best prognosis, with one study involving 200 cases reporting a 100% 5-year survival rate (8). In comparison, the same study reported Types B2, B3 and C thymomas to have 5-year survival rates of 75%, 70% and 48% respectively (8).

CT Thorax is the gold standard diagnostic and preoperative staging tool for thymomas (9). A general consensus of cumulative ionizing radiation that is accepted in pregnancy is <50mGy (10). The exposure from a single chest CT however is only <0.2mGy (11). In the early stages of the disease, they tend to be well-defined round or oval masses with preservation of fat planes between adjacent structures and the thymoma (9). The presence of irregular margins, calcifications, areas of low attenuations and the loss of clear fat planes suggest a more invasive nature (9). CT is a useful tool pre-operatively whereby it assists in identifying whether or not a thymoma can be surgically resected (9). It also aids with post-operative surveillance (9).

Mediastinal masses that appear as benign on CT (small-to medium in size without radiological evidence of local invasion) may be resected without requiring a pre-operative tissue diagnosis (9). In contrast, larger tumors or those with local invasion will require pre-operative biopsies to establish distinction from thymic carcinoma (9). However for our patient, we proceeded with a preoperative biopsy to ascertain the thymoma type preoperatively, as this would affect the decision of whether or not to proceed with surgery first or allow the pregnancy to continue and perform excision post-partum. As she was found to have a type B2 thymoma, the risk of progression to malignancy would have been higher than if she had, for example, a type A thymoma which would represent a relatively more benign pathology. This in turn would have affected her prognosis as the survival rates for types B3 and C thymomas are lower than those with type B2 as mentioned above. As such, surgery was undertaken as soon as the diagnosis was made.

Due to their malignant potential, all thymomas should be completely removed to prevent progression (9). Careful pre-operative planning and multidisciplinary team involvement is key to a successful outcome especially in cases where a resection or reconstruction of adjacently involved important structures such as the great vessels are required (9). Traditionally, thymectomies are performed via an open surgical method, namely gaining access to the thoracic cavity via a sternotomy or thoracotomy approach (12). However, there exist minimally invasive options through a variety of incisions and techniques including transcervical, extended transcervical, video-assisted thoracoscopy and robotic approaches (12). There have been limited reports on video-assisted thoracoscopic thymectomies in pregnancy. Nevertheless, VATS has been shown to be a safe and effective mode of treatment for lung cancer in pregnancy while resulting in less post-operative pain and faster recovery (13). Furthermore, our use of uniportal VATS does not require the use of carbon dioxide insufflation. Insufflation of carbon dioxide especially at high levels over an extended duration has been linked with fetal acidosis (14). Regardless of the approach, the general principle is to perform complete resection of the thymoma, and if this is not possible through a minimally-invasive approach, conversion to open surgery is required (12).

Pregnancy should not be a reason to delay necessary interventions as this can also affect maternal and fetal outcomes (13). Non-obstetric surgeries have been linked to a higher risk of a miscarriage and preterm labor (15). Hence, antenatal corticosteroids can be considered in patients with a viable fetus to promote lung maturity in the event of a preterm delivery (13). Perioperative assessment should take into account physiological changes in pregnancy such as the increase in cardiac output, oxygen consumption and coagulation factors (16). These patients should have a venous thromboembolism risk assessment done and if required, should be commenced on thromboprophylactic agents (13). The current literature shows no evidence of teratogenic effects of anaesthetic agents to fetuses when administered in standard doses (13). Intraoperative fetal monitoring should be decided on a case-to-case basis

and subject to certain factors such as gestational age and possibility of accommodating an emergency delivery during the planned procedure (13). Bearing all this in mind, it is paramount that a multidisciplinary team is involved, including the obstetric anesthetist as the ultimate goal is the safety of both mother and fetus (13).

Adjuvant therapy is not required for operable non-invasive thymomas (17). Complete resection of the thymoma precludes the need for post-operative radiotherapy or chemotherapy (8). However, there is a role of multimodal therapy encompassing surgery, radiotherapy and chemotherapy for more advanced stage thymomas that may not be completely resectable (17).

Conclusion

Thymomas can be the most common mass of the anterior mediastinum but when encountered in pregnancy, they pose different challenges altogether. Imaging in pregnancy should be considered where required. Maternal and fetal outcomes should be weighed when undertaking any major surgery in pregnancy especially when fetal viability has been reached. The safety of VATS in obstetric patients has been well described in the literature and its outcomes have been favorable. Complex cases should involve experts from the necessary field of expertise and a mutual decision with the patient should be sought. As with our patient, it is evident that it can be successfully managed with the right team.

Acknowledgments

The authors would like to thank the department of Obstetrics and Gynecology, Hospital Kuala Lumpur, and the department of general surgery, Hospital Kuala Lumpur.

Conflict of Interest

The authors have no conflict of interest.

References

1. Hsu CH, Chan JK, Yin CH, Lee CC, Chern CU, Liao CI. Trends in the incidence of thymoma, thymic carcinoma, and thymic neuroendocrine tumor in the United States. *PloS one*. 2019; 14(12):e0227197. [DOI:10.1371/journal.pone.0227197] [PMID] [PMCID]
2. Bian D, Zhou F, Yang W, Zhang K, Chen L, Jiang G, et al. Thymoma size significantly affects the survival, metastasis and effectiveness of adjuvant therapies: a population based study. *Oncotarget*. 2018; 9(15):12273. [DOI:10.18632/oncotarget.24315] [PMID] [PMCID]
3. Engels EA. Epidemiology of thymoma and associated malignancies. *J Thorac Oncol*. 2010; 5(10):S260-5. [DOI:10.1097/JTO.0b013e3181f1f62d] [PMID] [PMCID]

4. Pavlidis N, Zarkavelis G. Managing thoracic tumors during pregnancy. In *Managing Cancer during Pregnancy 2016* (pp. 185-191). Springer, Cham. [DOI:10.1007/978-3-319-28800-0_16]
5. Argubright KF, Mattox JH, Messer RH. Thymoma in pregnancy. *Obstet Gynecol Survey*. 1984; 39(4):185-91. [DOI:10.1097/00006254-198404000-00002] [PMID]
6. Kondo K, Yoshizawa K, Tsuyuguchi M, Kimura S, Sumitomo M, Morita J, Miyoshi T, Sakiyama S, Mukai K, Monden Y. WHO histologic classification is a prognostic indicator in thymoma. *Annals Thorac Surg*. 2004; 77(4):1183-8. [DOI:10.1016/j.athoracsur.2003.07.042] [PMID]
7. Dannhardt EC. Thymoma Staging. 2019. Available [here](#). Last accessed 17th May 2020.
8. Chen G, Marx A, Wen-Hu C, Yong J, Puppe B, Stroebel P, Mueller-Hermelink HK. New WHO histologic classification predicts prognosis of thymic epithelial tumors: a clinicopathologic study of 200 thymoma cases from China. *Cancer: Interdisciplinary Int J Am Cancer Soc*. 2002; 95(2):420-9. [DOI:10.1002/cncr.10665] [PMID]
9. Detterbeck FC, Zeeshan A. Thymoma: current diagnosis and treatment. *Chinese Med J*. 2013; 126(11):2186-91.
10. Eskandar O, Eckford S, Watkinson T. Safety of diagnostic imaging in pregnancy. Part 1: X-ray, nuclear medicine investigations, computed tomography and contrast media. *Obstet Gynaecol*. 2010; 12(2):71-8. [DOI:10.1576/toag.12.2.71.27571]
11. Whang B. Thoracic Surgery in the Pregnant Patient. *Thoracic Surgery in the Special Care Patient, An Issue of Thoracic Surgery Clinics*, E-Book. 2017 Oct 18;28(1):1-7. [DOI:10.1016/j.thorsurg.2017.08.002] [PMID]
12. Toker A, Sonett J, Zielinski M, Rea F, Tomulescu V, Detterbeck FC. Standard terms, definitions, and policies for minimally invasive resection of thymoma. *J Thorac Oncol*. 2011; 6(7):S1739-42. [DOI:10.1097/JTO.0b013e31821ea553] [PMID]
13. ACOG Committee. Nonobstetric Surgery During Pregnancy (Committee Opinion Number 775), 2017. Available [here](#). Last accessed 20th May 2020.
14. Kurihara K, Minagawa M, Masuda M, Fukuyama M, Tanigaki K, Yamamoto A, Kato S, Fujita H, Eto M. The evaluation of laparoscopic surgery on pregnant patients with ovarian cysts and its effects on pregnancy over the past 5 Years. *Gynecol Minim Invasive Ther*. 2018;7(1):1. [DOI:10.4103/GMIT.GMIT_12_17] [PMID] [PMCID]
15. Bogaerts A, Ameye L, Bijlholt M, Amuli K, Heynickx D, Devlieger R. INTER-ACT: prevention of pregnancy complications through an e-health driven interpregnancy lifestyle intervention-study protocol of a multicentre randomised controlled trial. *BMC pregnancy childbirth*. 2017; 17(1):1-9. [DOI:10.1186/s12884-017-1336-2] [PMID] [PMCID]
16. Bajwa SJ, Bajwa SK. Anaesthetic challenges and management during pregnancy: Strategies revisited. *Anesthesia, essays and researches*. 2013; 7(2):160. [DOI:10.4103/0259-1162.118945] [PMID] [PMCID]
17. Kondo K. Optimal therapy for thymoma. *J Med Invest*. 2008; 55(1, 2):17-28. [DOI:10.2152/jmi.55.17] [PMID].

How to Cite This Article:

Aran Sittampalam Y, AshaThayaparan N, Sathiamurthy N, Ganeshan M. A Mother with A Tumour Close To Her Heart: A Case Report on the Management of a Thymoma in Pregnancy. *J Obstet Gynecol Cancer Res*. 2021; 6 (3) :157-160

Download citation:

[BibTeX](#) | [RIS](#) | [EndNote](#) | [Medlars](#) | [ProCite](#) | [Reference Manager](#) | [RefWorks](#)