

Dermatofibrosarcoma Protuberans of the Vulva: A Report of 2 Cases of Unusual Localization

Tajossadat Allameh¹, Maryam Nazemi^{1*}, Leila Mousavi Seresht¹, Behnoosh Mohamadi²

1. Department of Obstetrics and Gynecology, Isfahan University of Medical Sciences, Isfahan, Iran
2. Departments of Pathology, Isfahan University of Medical Sciences, Isfahan, Iran



Article Info

[10.30699/jogcr.7.2.126](https://doi.org/10.30699/jogcr.7.2.126)

Received: 2021/04/21;

Accepted: 2021/05/27;

Published Online: 25 Oct 2021;

Use your device to scan and read the article online



Corresponding Information:

Maryam Nazemi,
Department of Obstetrics and Gynecology,
Isfahan University of Medical Sciences,
Isfahan, Iran
Email: Maryamnazemi2012@yahoo.com

ABSTRACT

This case report aimed to describe the clinical symptoms, pathological features, treatment, and prognosis of two cases of vulvar dermatofibrosarcoma protuberans (DFSP). Two Iranian women aged 37 and 35 presented with a nodular mass lesion in labia major and were initially diagnosed with DFSP in the vulva. Magnetic resonance imaging of the abdominopelvic region showed a small round lesion in the right side of the vulva vaginal region. The excisional procedure was performed under general anesthesia, and postoperative recovery was uneventful. Histopathology reported DFSP, which is a rare vulvar tumor. The patients were further investigated by computed tomography scan for metastasis, showing that the chest, abdomen, and pelvis were normal. The outcome was favorable. The DFSP is a rare tumor, constituting only 0.1% of all malignancies. Vulvar DFSP is exceptionally rare.

Keywords: Dermatofibrosarcoma protuberans, Unusual localization, Vulvar sarcoma



Copyright © 2022, This is an original open-access article distributed under the terms of the Creative Commons Attribution-noncommercial 4.0 International License which permits copy and redistribution of the material just in noncommercial usages with proper citation.

Introduction

Dermatofibrosarcoma protuberans (DFSP) of the vulva is a rare, slow-growing, low-to-intermediate-grade malignant tumor of the dermis layer of the skin classified as a sarcoma that usually invades the subcutaneous tissue and muscles (1-3). Although the exact cause of the DFSP of the vulva is unknown, studies have implicated a chromosomal translocation (4-6). The incidence of DFSP was 4.1 per million per year during 2000-2010 (7) or approximately 0.1% of all cancers and less than 1% of all sarcomas (8, 9). The tumor is seldom found in the vulva, with less than 50 cases currently reported in the medical literature (8, 10). The DFSP rarely leads to metastasis (fewer than 5% of cases). Vulvar DFSP is typically observed in middle-aged and older women and is diagnosed by biopsy. In most patients, it can be diagnosed using magnetic resonance imaging (MRI). The DFSP of the vulva grows slowly and presents for years before being noticed. They are painless when they are small, while large tumors can cause pain and discomfort due to pressure on the adjoining tissues and structures. The standard treatment techniques for resectable DFSP are complete surgical excision with wide the local excisions of 2 or 3 cm tumor-free margins (9, 11-13). Unresectable DFSPs are treated with radiation therapy.

The prognosis of the DFSP of the vulva is good and depends on the cancer stage, as well as the overall health of the individual. Here, we present the clinical symptoms, radiological features, pathological characteristics, treatment, and prognosis of two cases with vulvar DFSP.

Case Presentation

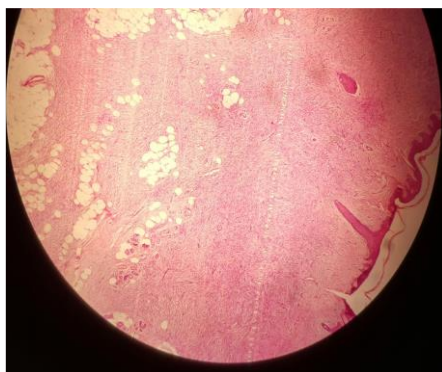
One of the patients was a 37-year old Iranian woman presented at the Gynecology Oncology Department of Shahid Beheshti Hospital affiliated to Isfahan University of Medical Sciences, Iran, with a non-tender nodular 3×2 cm² lesion of solid texture without ulceration and treatment history. The tumor was located in labia major (Figure 1), and lymphadenopathy was not noted. The patient stated that mass was present for at least 6 months and grew slowly. Preoperative pelvic MRI showed a small mass with heterogeneous enhancement in the right side of the vulva vagina. However, the cervix and uterus body were unremarkable and had subtle secretion in the canal cavity. In chest computerized tomography (CT)

and abdominopelvic ultrasonography, no metastatic disease was revealed. All routine blood tests and Pap smears were normal. Surgery was performed with wide local excision to obtain a 2 cm margin from the tumor. The patient had an uneventful postoperative recovery and was discharged after 2 days. The excised lesion of $7 \times 6 \times 3 \text{ cm}^3$ contained multiple nodular lesions, and the

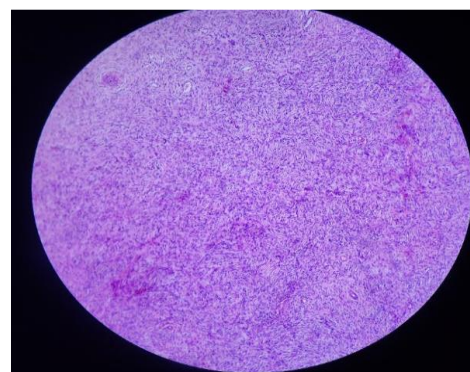
largest with the diameter of 2 cm was sent for histopathology showing DFSP. Histological examination demonstrated a storiform and honeycomb pattern, positively stained for CD 34 and vimentin indicating DFSP (Figure 2). After 11 months of follow-up, she was disease-free, and there is no evidence of recurrence.

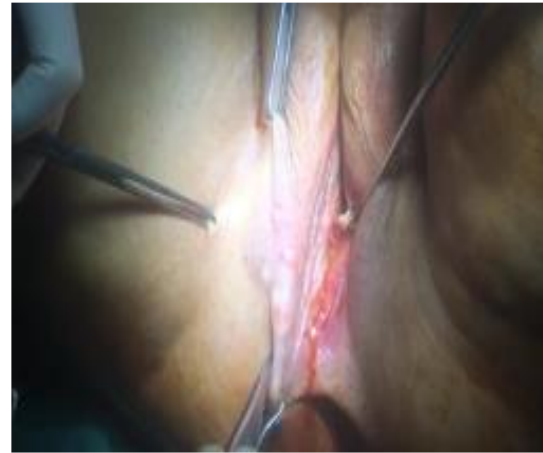
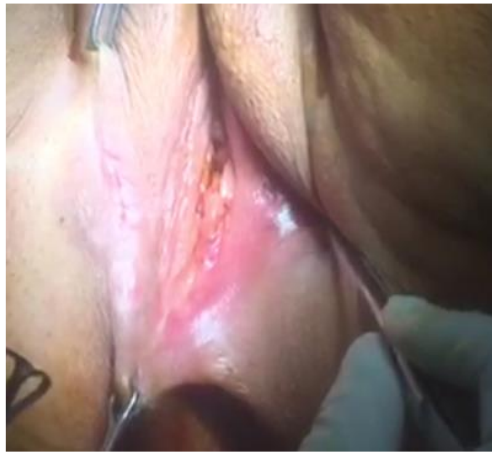
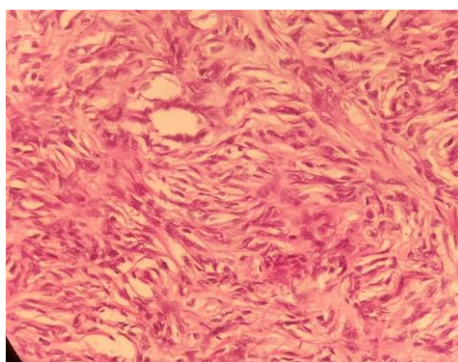
Figure 1. Preoperative photo of vulvar tumor showing right labia majora



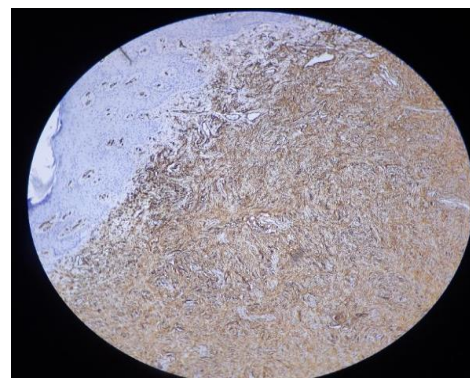
A



B



C



D

Figure 2. Honeycomb pattern interdigitates with lobules of subcutaneous fat (H and E, $\times 100$) A. Uniform population of slender fibroblasts arranged in storiform pattern (H and E, $\times 200$) B. and C. Diffuse cytoplasmic CD34 (C; H and E, $\times 100$) and vimentin (D; H and E, $\times 200$) positivity

The second case was a 35-year-old woman who presented to a gynecologic oncologist for a recurrent 2 cm mass lesion in labia major one year after the surgical resection of a nodular mass lesion. On clinical examination, a 3×3 cm, non-tender, pink, nodular lesion of solid texture was present on the right labium major without ulceration (Figure 1). Lymphadenopathy was not observed, and pathological examination reported DFSP. Ultrasonography revealed a heterogeneous mass of 35×9 mm² in labia major, which contained solid cyst with ill-defined area and infiltration in subcutaneous fat. All routine blood tests and Pap smears were normal. Chest and abdomen CT

showed no evidence of metastasis. The lesion was removed with 2 cm clear margins using a wide local excision technique. The excision involved the superficial and deep facial layers of the vulva. The remaining defect measured 6×3×2 cm and involved the right labium major and right upper inner thigh. The defect site was then repaired without the need for graft, and she was discharged home after 2 days. Specimens were sent for pathological examination, and DFSP was reported with a negative margin. This patient was followed for 3, 6, and 9 months (Figure 3) and was disease-free after 9 months.

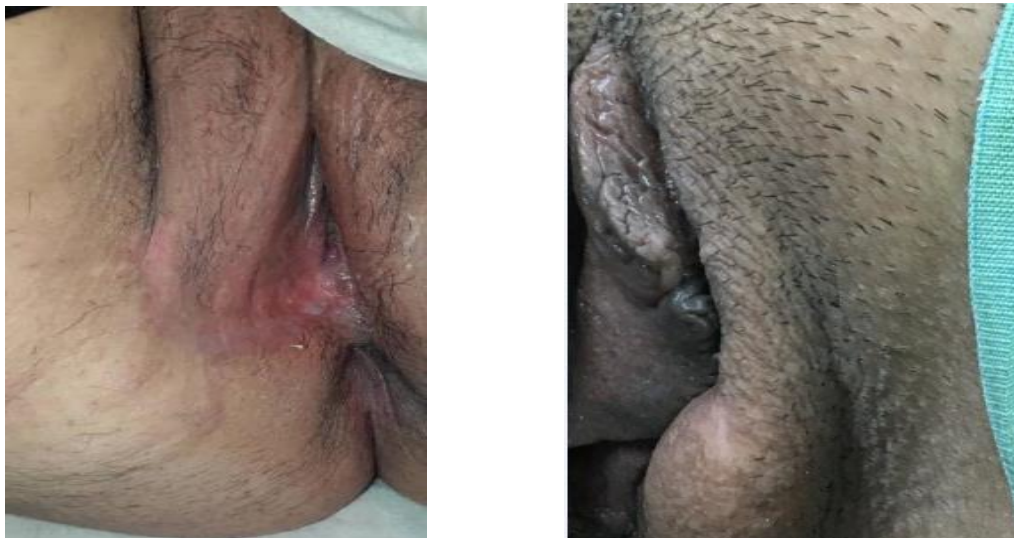

Figure 3. Postoperative photograph demonstrating healing at 9-month and 11-month follow-up

Discussion

The DFSP is a rare tumor, with studies in the United States indicating the incidence of this lesion as 4.2 per million people during 1973-2002 (14, 15) and 4.1 per million people during 2000-2010 (16). The most common sites of DFSP are trunk (42%-62%) (1, 8), extremities (16%-30%), as well as head and neck (10%-16%) (9). The DFSP in the vulva is extremely rare, with about 50 reported cases worldwide (1). Labia major was the most frequently affected site.

The DFSP is strongly stained for CD 34 and vimentin as seen on immunohistochemical studies in our cases (8). This tumor may be asymptomatic with an irregular nodule or violaceous plaque. It usually occurs as a solitary lesion (8). Our patients had multiple primary lesions that extend between the right vulva and groin. One of our patients had a history of recurrences. In sonography and CT scans, DFSP was a heterogeneous subcutaneous solid mass with speculated margins (17, 18). MRI can show the extension and depth of the lesion (1, 17). However, the diagnosis was confirmed only after a biopsy and pathologic examination.

The morphologic and molecular pathological findings of vulvar DFSP are similar to DFSP in other sites (19, 20). Translocation of chromosomes 17 and 22 (t(17:22)) is observed in over 90% of DFSPs (21). Currently, the exact cause of the development of vulvar DFSP is unclear, and no definitive risk factors have been reported. The suspicious factors contributing to DFSP entail the site of trauma (22), a region of extensive burns (23), surgical incision sites (24), vaccination sites (BCG vaccination) (25), arsenic poisoning (26), and other risk factors (27, 28). Age over 50 years appears to be a risk factor for local recurrence (29). Wide local excision surgery resection with a margin of 2-3 cm of normal tissue is recommended for both primary and recurrent DFSP.

Conclusion

In conclusion, our patients presented with clinically suspected symptoms of DFSP and were found to have vulvar DFSP after gynecological, surgical, and pathological assessments. It is suggested that DFSP in

middle-aged women may be misdiagnosed. Despite uncertainty concerning the underlying disease mechanism, DFSP can represent uncommon sites without specific symptoms. These cases allowed identifying known but rare clinical pictures of vulvar lesions.

Authors' Contributions

Allameh T, collected case materials, literature reviewed, wrote the manuscript, designed figures, and contributed to the discussion and revision of the manuscript. Also, the final revising and rewriting of

this manuscript were done by Allameh T, Nazemi M, Mousavi L. The pathology analysis of these cases were performed by Mohammadi B.

Acknowledgments

We express our gratitude to patients who consented to participate.

Conflict of Interest

The authors declared no conflict of interest.

References

- Torreggiani WC, Al-Ismail K, Munk PL, Nicolaou S, O'Connell JX, Knowing MA. Dermatofibrosarcoma protuberans: MR imaging features. *Am J Roentgenol*. 2002; 178:989-93. [DOI:10.2214/ajr.178.4.1780989] [PMID]
- Gilani S, Al-Khafaji B. Dermatofibrosarcoma protuberans of the vulva: a mesenchymal tumour with a broad differential diagnosis and review of literature. *Pathologica* 2014; 106: 338-41.
- Asiri M, Moghazy KM, Alsaif HS, Al-Qahtani MS. Dermatofibrosarcoma Protuberance: a case report and review of literature. *Biomed Res*. 2008; 19: 141-4.
- Simon MP, Pedeutour F, Sirvent N, Grosgeorge J, Minoletti F, Coindre JM, et al: Deregulation of the platelet-derived growth factor B-chain gene via fusion with collagen gene COL1A1 in dermatofibrosarcoma protuberans and giant cell fibroblastoma. *Nat Genet* 1997; 15: 95-8. [DOI:10.1038/ng0197-95] [PMID]
- Shah KK, McHugh JB, Folpe AL, Patel RM. Dermatofibrosarcoma protuberans of distal extremities and acral sites: A clinicopathologic analysis of 27 cases. *Am J Surg Pathol* 2018; 42: 413-9. [DOI:10.1097/PAS.0000000000000998] [PMID]
- Hao X, Billings SD, Wu F, Stultz TW, Procop GW, Mirkin G, et al. Dermatofibrosarcoma Protuberans: Update on the Diagnosis and Treatment. *J Clin Med* 2020; 9: 1752. [DOI:10.3390/jcm9061752] [PMID] [PMCID]
- Larbcharoensub N, Kayankarnavee J, Sanpaphant S, Kiranantawat K, Wirojtananugoon C, Sirikulchayanonta V. Clinicopathological features of dermatofibrosarcoma protuberans. *Oncol. Lett*. 2016; 11: 661-7. [DOI:10.3892/ol.2015.3966] [PMID] [PMCID]
- Hammonds LM, Hendi A. Dermatofibrosarcoma protuberans of the vulva treated using mohs micrographic surgery. *Dermatol Surg*. 2010; 36:558-63. [DOI:10.1111/j.1524-4725.2010.01493.x] [PMID]
- Smola MG, Soyer HP, Scharnagl E. Surgical treatment of dermatofibrosarcoma protuberans. A retrospective study of 20 cases with review of literature. *Eur J Surg Oncol*. 1991;17: 447-53.
- Edelweiss M., Malpica A. Dermatofibrosarcoma protuberans of the vulva: a clinicopathologic and immunohistochemical study of 13 cases. *Am J Surg Pathol* 2010;34:393-400. [DOI:10.1097/PAS.0b013e3181cf7fc1] [PMID]
- Doufekas K, Duncan TJ, Williamson KM, Varma S, Nunns D. Mohs micrographic surgery for dermatofibrosarcoma protuberans of the vulva. *Obstet Gynecol Int* 2009; 2009:1-2. [DOI:10.1155/2009/547672] [PMID] [PMCID]
- Farma JM, Ammori JB, Zager JS, Marzban SS, Bui MM, Bichakjian CK, et al. Dermatofibrosarcoma protuberans: how wide should we resect? *Ann Surg Oncol* 2010;17:2112-8. [DOI:10.1245/s10434-010-1046-8] [PMID]
- Häfner HM, Moehrle M, Eder S, Trilling B, Röcken M, Breuninger H. 3DHistological evaluation of surgery in dermatofibrosarcoma protuberans and malignant fibrous histiocytoma: Differences in growth patterns and outcome. *Eur J Surg Oncol* 2008; 34:680-6. [DOI:10.1016/j.ejso.2007.07.004] [PMID]
- Criscione VD, Weinstock MA. Descriptive epidemiology of dermatofibrosarcoma protuberans in the United States, 1973 to 2002. *J Am Acad Dermatol* 2007;56:968-73. [DOI:10.1016/j.jaad.2006.09.006] [PMID]

15. Kreicher KL, Kurlander DE, Gittleman HR, Barnholtz-Sloan JS, Bordeaux JS. Incidence and Survival of primary Dermatofibrosarcoma Protuberans in the United States. *Dermatol Surg* 2016;42(Suppl. 1):S24-S31. [[DOI:10.1097/DSS.0000000000000300](https://doi.org/10.1097/DSS.0000000000000300)] [[PMID](#)]
16. Kransdorf MJ, Meis-Kindblom JM. Dermatofibrosarcoma protuberans: Radiologic appearance. *Am J Roentgenol* 1994;163:391-4. [[DOI:10.2214/ajr.163.2.8037038](https://doi.org/10.2214/ajr.163.2.8037038)] [[PMID](#)]
17. Mendenhall W, Zlotecki R, Scarborough M. Dermatofibrosarcoma protuberans. *Cancer* 2004; 101: 2503-8. [[DOI:10.1002/cncr.20678](https://doi.org/10.1002/cncr.20678)] [[PMID](#)]
18. Vanni R, Faa G, Dettori T, Melis GB, Dumanski JP, O'Brien KP. A case of dermatofibrosarcoma protuberans of the vulva with a COL1A1/PDGFB fusion identical to a case of giant cell fibroblastoma. *Virchows Arch*. 2000;437(1):95-100. [[DOI:10.1007/s00428000184](https://doi.org/10.1007/s00428000184)] [[PMID](#)]
19. Gokden N, Dehner LP, Zhu X, Pfeifer JD. Dermatofibrosarcoma protuberans of the vulva and groin: detection of COL1A1-PDGFB fusion transcripts by RT-PCR. *J Cutan Pathol* 2003;30:190-5. [[DOI:10.1034/j.1600-0560.2003.00037.x](https://doi.org/10.1034/j.1600-0560.2003.00037.x)] [[PMID](#)]
20. Mbonde MP, Amir H, Kitinya JN. Dermatofibrosarcoma protuberans: a clinicopathological study in an African population. *East Afr Med J* 1996; 73: 410-3.
21. Kreicher KL, Kurlander DE, Gittleman HR, Barnholtz-Sloan JS, Bordeaux JS. Incidence and Survival of primary Dermatofibrosarcoma Protuberans in the United States. *Dermatol Surg*. 2016; 42(Suppl. 1):S24-S31. [[DOI:10.1097/DSS.0000000000000300](https://doi.org/10.1097/DSS.0000000000000300)] [[PMID](#)]
22. Bashara ME, Jules KT, Potter GK. Dermatofibrosarcoma protuberans: 4 years after local trauma. *J Foot Surg* 1992;31:160-5.
23. Tanaka A, Hatoko M, Tada H, Kuwahara M, Iioka H, Niitsuma K. Dermatofibrosarcoma protuberans arising from a burn scar of the axilla. *Ann Plast Surg*. 2004;52:423-5. [[DOI:10.1097/01.sap.0000100421.95683.9b](https://doi.org/10.1097/01.sap.0000100421.95683.9b)] [[PMID](#)]
24. Argiris A, Dardoufas C, Aroni K. Radiotherapy induced soft tissue sarcoma: an unusual case of a dermatofibrosarcoma protuberans. *Clin Oncol (R Coll Radiol)* 1995;7:59-61. [[DOI:10.1016/S0936-6555\(05\)80641-7](https://doi.org/10.1016/S0936-6555(05)80641-7)]
25. Green JJ, Heymann WR. Dermatofibrosarcoma protuberans occurring in a smallpox vaccination scar. *J Am Acad Dermatol* 2003;48:S54-S55. [[DOI:10.1067/mjd.2003.168](https://doi.org/10.1067/mjd.2003.168)] [[PMID](#)]
26. Bukhari I, Al Akloby O, Bedaiwi Y. Dermatofibrosarcoma protuberans at the site of a central venous line. Case report. *Am J Clin Dermatol*. 2005; 6: 61-4. [[DOI:10.2165/00128071-200506010-00007](https://doi.org/10.2165/00128071-200506010-00007)] [[PMID](#)]
27. Lehmer LM, Ragsdale BD. Digital dermatofibromas - common lesion, uncommon location: a series of 26 cases and review of the literature. *Dermatol Online J*. 2011;17:2. [[DOI:10.5070/D32HG6Q36K](https://doi.org/10.5070/D32HG6Q36K)] [[PMID](#)]
28. Behranwala KA, Latifaj B, Blake P, Barton DPJ, Shepherd JH, Thomas JM. Vulvar soft tissue tumors. *Int J Gynecol Cancer*. 2004;14:94-9. [[DOI:10.1136/ijgc-00009577-200401000-00012](https://doi.org/10.1136/ijgc-00009577-200401000-00012)] [[PMID](#)]
29. Noujaim J, Thway K, Fisher C, Jones RL. Dermatofibrosarcoma protuberans: from translocation to targeted therapy. *Cancer Biol Med*. 2015;12:375-84.

How to Cite This Article:

Allameh T, Nazemi M, Mousavi Seresht L, Mohamadi B. Dermatofibrosarcoma protuberans of the vulva: a Report of 2 Cases of Unusual Localization. *J Obstet Gynecol Cancer Res*. 2022;7(2):126-130.

Download citation:

[BibTeX](#) | [RIS](#) | [EndNote](#) | [Medlars](#) | [ProCite](#) | [Reference Manager](#) | [RefWorks](#)

Send citation to:

 Mendeley  Zotero  RefWorks