

Rhabdomyosarcoma of the Cervix in Adult is Fertility Preservation Possible? Report of Two Cases

Fariba Behnamfar ¹ , Maryam Nazemi ^{1*} , Fereshteh Mohammadizadeh ² 

1. Departments of Women's Oncology, School of Medicine, Isfahan University of Medical Science, Isfahan, Iran
2. Departments of Pathology, School of Medicine, Isfahan University of Medical Science, Isfahan, Iran



Article Info

doi [10.30699/jogcr.7.3.247](https://doi.org/10.30699/jogcr.7.3.247)

Received: 2021/04/22;

Accepted: 2021/08/29;

Published Online: 12 Jan 2022;

Use your device to scan and read the article online



Corresponding Information:

Maryam Nazemi,

Departments of Women's Oncology, School of Medicine, Isfahan University of Medical Science, Isfahan, Iran

Email: maryamnazemi2012@yahoo.com

ABSTRACT

Rhabdomyosarcoma (RMS) is a rare type of sarcoma. Botryoid type is the most common. The peak incidence is the second decade. Cervical RMS is rare in adults. We reported two cases, A, 31 years old woman G1L1 referred to a gynecologist oncologist with abnormal vaginal bleeding. And pathology reported RMS. She received 8 courses of VAC regimen for chemotherapy. 3 weeks after the last course, she underwent conization, and a remnant of sarcoma was seen. A hysterectomy was done for her. She has been disease free for 12 months. Case 2 was a 25 years old nulliparous woman presenting with abnormal vaginal bleeding, vaginal discharge, and cervical polypoid grape like lesion. Pathology reported RMS. Conization was done. Chemotherapy with a VAC regimen was done for 8 courses. She has been disease free after 9 years. These two cases showed that RMS could occur in rare places and older ages.

Keywords: Rhabdomyosarcoma (RMS), Cervical, Embryonal botryoid type



Copyright © 2021, This is an original open-access article distributed under the terms of the Creative Commons Attribution-noncommercial 4.0 International License which permits copy and redistribution of the material just in noncommercial usages with proper citation.

Introduction

Cervical sarcoma is a rare tumor, and also, RMS is a rare malignant skeletal muscle tumor that is rare (1). The embryonal subtype has been subdivided into classic, botryoid, and spindle cells (2). Cervical embryonal RMS are often a type of botryoid variant (3). The most typical presenting symptom is vaginal bleeding.

Case Presentation

CASE 1

31 years old woman G1L1 presented with a complaint of abnormal vaginal bleeding. She was referred to a gynecologist oncologist because of a cervical lesion. The polypoid mass grape-like lesion was hyperemic and fragile 3 cm in diameter and the cervix's anterior lip in colposcopy examination. Biopsy was done, and Botryoid sarcoma was reported (Figure 1, 2). Microscopic examination revealed small round or spindle cells in a rather myxoid stroma. RMS differentiation as abundant eosinophilic cytoplasm and eccentric nuclei was seen in some cells. Tumor cell condensation beneath the squamous epithelium, forming the cambium layer of Nicholson, was evident.

C_t imaging of thorax and abdominopelvic was normal. She received eight courses of vincristine, actinomycin, cyclophosphamide (VAC) regimen. Vincristine (1.5 mg/m², iv, d1), Dactinomycin (0.5 mg/kg, iv, d1-d5), cyclophosphamide (300 mg/m², iv, d1-d5) every four weeks. The total length of treatment usually ranges from 6 months to a year.

Three weeks after the end of chemotherapy, the growth appearance of the cervix was highly suspicious for tumor. (Figure 3) She was scheduled for conization surgery, endocervical curettage, and endometrial biopsy. Pathology reported minimal residue of cancer. So, the patient candidate for hysterectomy and underwent a hysterectomy. The margin of surgery was free of tumors.

Physical examination was done every 3 months, and she had no pathologic signs. In the first two years, we visit the patient every three months. The visit interval can be increased to six months, and the follow-up can be continued for five years. She has been disease free for 12 months.

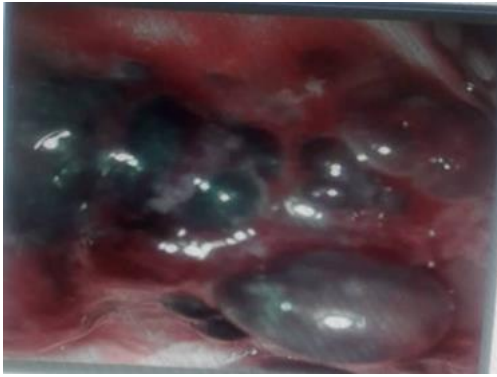


Figure 1. Exophytic lesion on colposcopic examination.

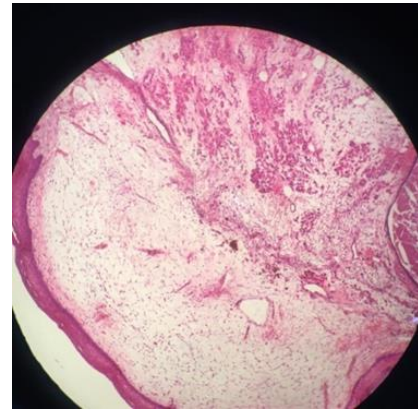


Figure 2. Pathology view

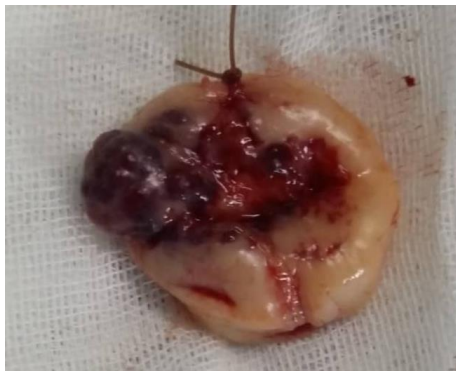

Figure 3. Conization view.

CASE 2

A 25 years old nulliparous woman complained of abnormal vaginal bleeding and vaginal discharge from

four months earlier. Her endocervical and endometrial curettage was reported normal 2 months ago. In the vaginal examination, the cervical polypoid grape like mass lesion 36×63 mm was seen. Biopsy was done, and Botryoid sarcoma was reported (Figure 4, 5). As rapid regrowth of cervical tumor in three weeks happened, cervical conization surgery was done under anesthesia. No tumor residues were reported in pathology, and the chemotherapy, including the (VAC) regime, was started. Chemotherapy continued for 3cycle. She was amenorrheic for 12 month and FSH level was 100 IU/L (1.09-9.2 IU/L). But menstruation restarted regulated after that.

2 weeks after chemotherapy, ECC and EMC were done, and pathology was reported normal. In follow-up, every 3 months, she has no pathologic signs, and after 9 years, she has been disease free with no recurrence.

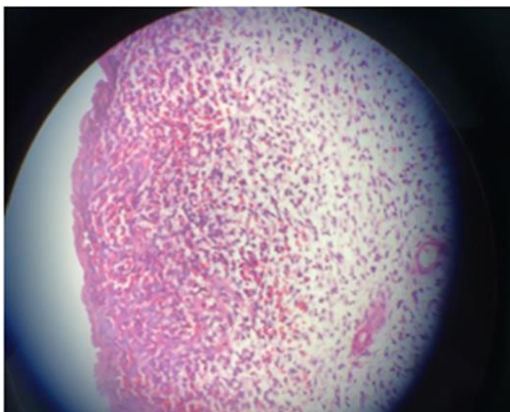


Figure 4. Medium power view (x 100): cambium layer

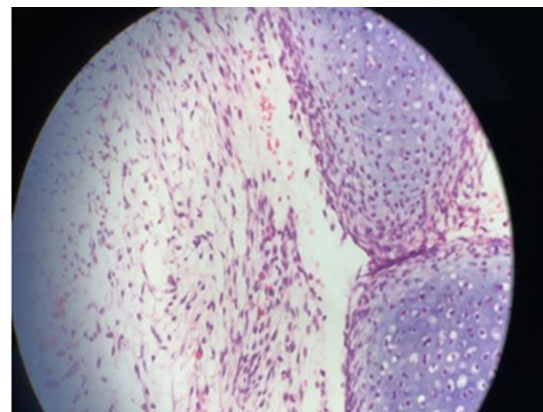


Figure 5. Medium power view (x 100): nodules of immature cartilage within the tumor.

Discussion

We present one case of 31 years woman G1L1 with cervical RMS diagnosed in a cervical polyp and the other case 25 years old nulliparous woman with cervical mass.

Visual inspection of the cervix in these patients was abnormal. The diagnosis was only confirmed after a biopsy and pathology exam. These two cases showed that RMS could occur in rare places and older ages. Adults are more likely to resist chemotherapy.

RMS are rare in adults; compared to children, it accounts for half of the sarcoma cases (1). In patients, cervical RMS presents as a cervical mass or polyp” (4).

Immunohistochemistry stains can aid in diagnosis. Myogenin was the most specific and sensitive marker for RMS (5).

The differential diagnosis for cervical polypoid lesions in women includes endometriosis, cervical or endometrial polyps, adenofibroma, adenosarcoma, and lymphoma (3).

Approach to management have varied over the years, but radical surgery, for primary management, has progressively been replaced by chemotherapy (VAC) and more conservative surgery (6).

Standard treatment in pediatric is chemotherapy and fertility preservation.

Chemotherapy with VAC and radiation therapy concurrently may start on week4 of treatment (7). A SEER study showed that the five years overall survival in adults with RMS was 27% compared to 61% in children (8).

Although adults with RMS had generally worse survival than children, Cervical botryoid RMS has better survival and prognosis than vaginal lesions in children. The survival rate of vaginal and cervical lesions has been reported to be 96% and 60% (9).

These cases showed that adult patients with RMS might not present the typical cervical lesion. Also, more data on the treatment and survival of adults with cervical RMS are needed.

Conclusion

In conclusion, these cases showed that adult patients with RMS might not present with the typical cervical lesion. Also, RMS can occur in rare places and at an older age, and fertility preservation is possible. More data on the treatment and survival of adults with cervical RMS are needed.

Acknowledgments

We express our gratitude to patients who consented to participate

Financial Conflict

The authors state that they do not have a conflict of interest and do not oppose the publication of this study

Funding/Supports

This paper has no sponsor

Conflicts of Interests

The authors declared no conflict of interest.

References

1. Ries LA, Harkins D, Krapcho M, Mariotto A, Miller BA, Feuer EJ, et al. SEER cancer statistics review, 1975-2003. 2006.
2. Kriseman ML, Wang WL, Sullinger J, Schmeler KM, Ramirez PT, Herzog CE, et al. Rhabdomyosarcoma of the cervix in adult women and younger patients. *Gynecol Oncol*. 2012;126(3):351-6. [PMID] [PMCID] [DOI:10.1016/j.ygyno.2012.05.008]
3. Dehner LP, Jarzembowski JA, Hill DA. Embryonal rhabdomyosarcoma of the uterine cervix: a report of 14 cases and a discussion of its unusual clinicopathological associations. *Mod Pathol*. 2012;25(4):602-14. [PMCID] [DOI:10.1038/modpathol.2011.185] [PMID]
4. Hosseini MS, Ashrafganjoei T, Sourati A, Tabatabeifar M, Mohamadianamiri M. Rhabdomyosarcoma of Cervix: A Case Report. *Iran J Cancer Prev*. 2016;9(3):e4383. [DOI:10.17795/ijcp-4383] [PMID] [PMCID]
5. Morotti RA, Nicol KK, Parham DM, Teot LA, Moore J, Hayes J, et al. An immunohistochemical algorithm to facilitate diagnosis and subtyping of rhabdomyosarcoma: the Children's Oncology Group experience. *Am J Surg Pathol*. 2006; 30(8):962-8. [PMID] [DOI:10.1097/0000478-200608000-00005]
6. Magné N, Oberlin O, Martelli H, Gerbaulet A, Chassagne D, Haie-Meder C. Vulval and vaginal rhabdomyosarcoma in children: update and reappraisal of Institut Gustave Roussy brachytherapy experience. *Int J Radiat Oncol Biol Phys*. 2008;72(3):878-83. [DOI:10.1016/j.ijrobp.2008.01.034] [PMID]
7. Bradley JA, Kayton ML, Chi Y-Y, Hawkins DS, Tian J, Breneman J, et al. Treatment Approach and Outcomes in Infants with Localized Rhabdomyosarcoma: A Report From the Soft Tissue Sarcoma Committee of the Children's Oncology Group. *International journal of radiation oncology, biology, physics*. 2019;103(1):19-27. [PMID] [PMCID] [DOI:10.1016/j.ijrobp.2018.08.017]

8. Hawkins DS, Chi YY, Anderson JR, Tian J, Arndt CAS, Bomgaars L, et al. Addition of Vincristine and Irinotecan to Vincristine, Dactinomycin, and Cyclophosphamide Does Not Improve Outcome for Intermediate-Risk Rhabdomyosarcoma: A Report From the Children's Oncology Group. *J Clin Oncol.* 2018;36(27):2770-7. [\[PMID\]](#) [\[PMCID\]](#) [\[DOI:10.1200/JCO.2018.77.9694\]](#)
9. Sultan I, Qaddoumi I, Yaser S, Rodriguez-Galindo C, Ferrari A. Comparing adult and pediatric rhabdomyosarcoma in the surveillance, epidemiology, and end results program, 1973 to 2005: an analysis of 2,600 patients. *J Clin Oncol.* 2009;27(20):3391-7. [\[DOI:10.1200/JCO.2008.19.7483\]](#) [\[PMID\]](#)

How to Cite This Article:

Behnamfar F, Nazemi M, Mohammadizadeh F. Rhabdomyosarcoma of the Cervix in Adult is Fertility Preservation Possible? Report of Two Cases. *J Obstet Gynecol Cancer Res.* 2022; 7 (3) :247-250

Download citation:

[BibTeX](#) | [RIS](#) | [EndNote](#) | [Medlars](#) | [ProCite](#) | [Reference Manager](#) | [RefWorks](#)