





COVID-19 Infection in Iranian Pregnant Women: A Case Series of 25 Patients

Maryamsadat Hosseini¹ , Farah Farzaneh^{1*} , Mahsa Mirhadi¹, Seyed Ali Akbar Mahdavi Anari² , Ladan Ajori¹ , Saghar Salehpour¹ , Tayebbeh Jahed Bozorgan¹ , Parichehr Pooransari¹ , Shideh Ariana¹, Minoo Yaghmaei¹ , Behnaz Nouri¹, Shahrzad Zadehmodarres¹ , Sedighe Hosseini¹ , Mehrdad Haghghi³, Mir Mohammad Miri⁴ , Seyedpouzhia Shojaei⁴ , Ali Reza Mirkheshti⁴ , Dariush Abtahi⁵ , Tannaz Valadbeigi⁶

1. Department of Obstetrics and Gynecology, Preventative Gynecology Research Center, Shahid Beheshti University of Medical Sciences, Tehran, Iran
2. Department of Radiology, Shahid Beheshti University of Medical Sciences, Tehran, Iran
3. Department of Infectious Disease, Infectious Diseases and Tropical Medicine Research Center, Imam Hossein Hospital, Shahid Beheshti University of Medical Sciences, Tehran, Iran
4. Department of Anesthesiology, School of Medicine, Shahid Beheshti University of Medical Sciences, Tehran, Iran
5. Department of Anesthesiology, Anesthesiology Research Center, Shahid Beheshti University of Medical Sciences, Tehran, Iran
6. Department of Epidemiology and Biostatistics, School of Public Health, Tehran University of Medical Sciences, Tehran, Iran



Article Info

 [10.30699/jogcr.7.4.286](https://doi.org/10.30699/jogcr.7.4.286)

Received: 2021/08/18;

Accepted: 2021/10/16;

Published Online: 14 Mar 2022;

Use your device to scan and read the article online



Corresponding Information:

Farah Farzaneh,
Department of Obstetrics and Gynecology,
Preventative Gynecology Research Center,
Shahid Beheshti University of Medical
Sciences, Tehran, Iran
Email: farahzaneh@yahoo.com

ABSTRACT

Background & Objective: The COVID-19 infection remains a major pandemic threatening global health. Studies revealed that pregnant women are more prone to develop severe illness, with an increased risk of morbidity and mortality. So the objective of this study is to report the clinical presentation and perinatal outcomes after COVID-19 infection during pregnancy or the puerperium.

Materials & Methods: In this case series study, since February 2020, 25 pregnant women with a definitive diagnosis of the COVID-19 infection were registered. Their clinical signs and symptoms, laboratory findings, CT manifestations, pregnancy status, were recorded at the first visit, and they were followed six months after diagnosis.

Results: The most common symptoms were cough, feeling feverish, and dyspnea. Twenty mothers required hospitalization, 5 out of 20 monitored in COVID-ICU. The chest CT scan demonstrated a grand glass appearance in 77% of cases among admitted patients. The total mortality rate in C-ICU (COVID-19 ICU) admitted patients were 80%.

Conclusion: In this case series, among 25 pregnant women with confirmed COVID-19, the most vulnerable patients were in the early third trimester and twin pregnancy.

Keywords: COVID-19, CT scan, PCR, Pregnancy



Copyright © 2022, This is an original open-access article distributed under the terms of the Creative Commons Attribution-noncommercial 4.0 International License which permits copy and redistribution of the material just in noncommercial usages with proper citation.

Introduction

Based on the World Health Organization (WHO) announcement, published on 30 January 2020, the COVID-19 pandemic is the sixth public health emergency of international concern, following H1N1 (2009), polio (2014), Ebola West Africa (2014), Zika (2016) and Ebola in the Democratic Republic of Congo (2019).

The mortality rate of this acute resolving disease is about 2%, mostly due to massive alveolar damage and

progressive respiratory failure (1-2), and less common due to severe heart complications, digestive symptoms, and skin manifestations (3-6). According to previous studies, COVID-19 PCR testing and/or Chest CT scan are the gold standard diagnostic methods (7-10).

Although after nearly one year of investigations, the data revealed that pregnant women with COVID-19 are at increased risk of severe COVID-19, still, many questions remain (11-14). Some case reports and case

series lead to overestimating risks because outpatients or uncomplicated pregnant women are not considered.

The aim of this case series is to report the outcome of 25 pregnant women infected with COVID-19 registered in four large university hospitals in Tehran.

Methods

In this case series, the course of the disease and the outcome of 25 pregnant women diagnosed with COVID-19 are reported during one year. All women were referred to 4 university hospitals: Taleghani, Tajrish, Imam Hossein, and Mahdih, Tehran, Iran. The clinical signs and symptoms, laboratory findings, and CT manifestations of these infected pregnant women are reported. The patients' condition and pregnancy outcomes were monitored for 6 to 12 months after diagnosis. All survived women (not admitted or discharged from the hospitals) were visited every week for one month and monthly for six months.

Since February 2020, all pregnant women suspected of being infected with COVID-19 referred to 4 university hospitals were triaged for oxygen (O₂) saturation, fever, and other disease-related symptoms, based on WHO guidelines (15). In case of strong suspicion, COVID-19 PCR was performed (using nasopharyngeal or oropharyngeal swabs) on patients. A chest CT scan was also done (if indicated). In case of a definitive diagnosis of the disease (based on chest CT scan or PCR), subjects were registered in our study.

The demographic information, initial symptoms and their duration, past obstetric, medical, surgical, and drug history were noted. For all pregnant women, maternal vital signs, O₂ saturation, laboratory tests, and pregnancy status were recorded.

Patients were either treated on an outpatient basis, admitted into the COVID-19 Ward (C-Ward) or COVID-19 ICU (C-ICU) based on their obstetric condition and infectious status.

All CT images were reported by an experienced radiologist. The manifestation of lung involvement in the axial and coronal CT imaging was classified, and the severity of each lobe involvement was scored according to the percentage of involvement: <5% score 1, 5%-25% score 2, 26%-49% score 3, 50%-75% score 4, and >75% score 5. And the total chest CT score of the patient is equal to the sum of each lobe involvement and can range from 0 (no involvement) to 25 (maximum involvement).

If pregnancy terminated during the active phase of COVID-19 infection, the newborn was immediately isolated from the mother and tested for COVID-19 PCR. The neonates' conditions, including Apgar score, birth weight, oxygen requirement, or need for antiviral treatment were recorded.

Results

Data were analyzed using SPSS version 23 (SPSS Inc., Chicago, Ill., USA). Frequency and percentage were used to describe qualitative variables and chart to compare patients' symptoms.

Over one year, from February 2020 to February 2021, 25 pregnant women with the mean age of 32 (19-48 years) infected by COVID-19 were registered in our database. COVID-19 PCR testing was reported positive in 24 (96%) patients.

Five mothers with mild illness, mostly less than 25 weeks of pregnancy, were treated as outpatients. Fifteen patients were admitted to C-Ward (66% > 30 weeks), and 5 were monitored in C-ICU, mostly (26-30weeks).

About 50% experienced their first pregnancy, 12% had one or two abortions in the past, and there was no history of IUFD or neonatal death. Two mothers had twin pregnancies, both with a history of infertility (IVF and ICSI).

Eleven patients (44%) had a contact history with infected patients. None of 25 infected pregnant women were vaccinated against flu before contracting COVID-19.

The five most common symptoms at the first visit were cough (72%), feeling feverish (68%), dyspnea (60%), sweating (52%), decrease or loss of taste or smell (52%) (Figure 1).

The vital signs of all outpatients were normal, and their O₂ saturation was above 95%.

Among twenty admitted patients, 17 women needed O₂ therapy, including 3 patients who were intubated in C-ICU with O₂ saturation ≤ 90 % (86-90%). Six patients, had respiratory rate > 22 breath/min. Nine patients (45%) had the oral T > 37.7°C, and 2 had blood pressure > 140/90 mmHg. Ten patients (50%) were tachycardic.

The most common abnormal laboratory findings were related to CRP and ESR.

Chest CT scan was performed for 13 admitted pregnant women based on clinical necessity. The frequency of chest CT abnormality was not significantly different in 5 different lobes (77-92%). The majority of Chest CT scans demonstrated a ground glass appearance (77%) (Table 1). The highest severity of pulmonary involvement was related to intubated patients. Three patients had a CT severity score > 13, all intubated in the C-ICU.

The Data of all 25 pregnant women with COVID-19 infections are listed in Table 2.

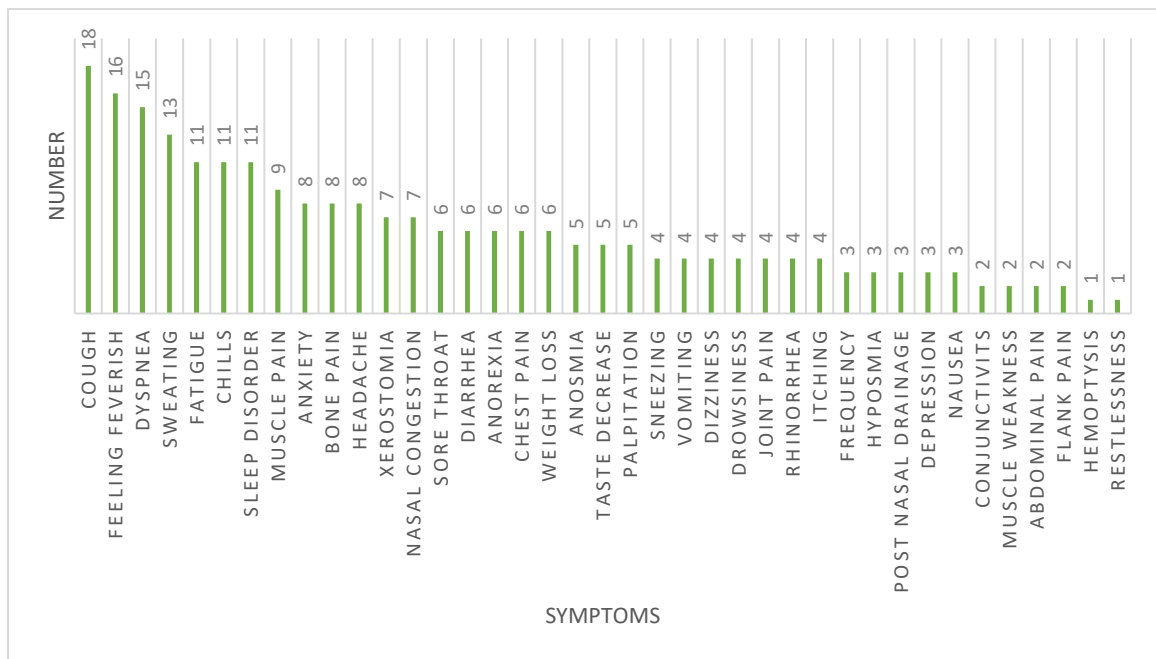


Figure 1. The frequency of symptoms in infected women with COVID-19

Table 1. Chest CT scan report in 13 admitted pregnant patients with COVID-19 infection

Variable	N0. Patients (%)
Ground glass	10 (77)
Consolidation	6 (46)
Crazy paving	6 (46)
Vascular thickening	4 (31)
Pleural effusion	1 (8)
Reversed Halo sign	0
Lymphadenopathy	0

Table 2. The Chief Complaints, Clinical Characteristics, Treatments, and Outcomes of 5 outpatients, 20 C-Ward and 5 C-ICU admitted Women with COVID-19 infections

	Presenting complaints	GA	M Age	CT score	Respiratory Status	H p/day	Medical treatment	Mother status	Complication	Neonate status
1*	Feeling feverish, cough, dyspnea	23w+3d Twin	35	14	Invasive ventilation	10	H.Chl/ Azi/ Kaletra/ oseltamivir/ ceftriaxone/ DiPhen/ vancomycin/ meropenem/ IVIG=60mg/FFP=2/Pack cell=2	Dead	Myocarditis	IUFD
2*	FOF and chills, cough, dyspnea	28w+2d Twin	48	20	Invasive ventilation	16	H.Chl/ Kaletra/ oseltamivir/ DiPhen/ vancomycin/ meropenem/ IVIG=60mg/ plasmapheresis/ Corticosteroid/ Tocilizomab/ Ribavirin	Dead	NEG	Dead (DIC)
3*	Itching 6 mo/	27w+6d	25	11	O2 with mask	18	H.Chl/ Azi/ ceftriaxone/ kaletra/ oseltamivir/	Dead	Cholestasis liver failure	Dead (RDS)

	Presenting complaints	GA	M Age	CT score	Respiratory Status	H p/day	Medical treatment	Mother status	Complication	Neonate status
	cough/jaundice 2 weeks						corticosteroid/cefazolin/metronidazole / FFP=11			
4*	dyspnea	39w	32	21	Invasive ventilation	9	H.Chl / ceftriaxone/ kaletra/ corticosteroid/ IVIG=60 mg/ interferon=5/ PLT=9/pack cell=1	Good	NEG	NL4
5*	cough, dyspnea	29w+6d	27	-	O2 with mask	31	H.Chl /betamethasone/ MgSO ₄ / Indomethacin / Digoxin/ Isordil/ hydalazine	Heart failure	Myocarditis /preterm labor	NL
6**	Cough, dyspnea, diarrhea	17w+1d	35	-	O2 with mask	4	H.Chl / Azi/ ceftriaxone/ DiPhen	Good	NEG	NL
7**	labor pain	36w+6d	35	0	Room air	1	No treatment	Good	NEG	NL
8**	FOF, chills, dry cough	19w+3d	31	5	O2 with mask	9	H.Chl/ Azi/ ceftriaxone/ kaletra/ oseltamivir/ salbutamol	Good	NEG	NL
9**	Cough, dyspnea	26w	35	9	O2 with mask	5	H.Chl/ Azithromycin	Good	NEG	NL
10**	vaginal leak	38w+1d	21	-	O2 with mask	5	H.Chl/ kaletra	Good	Thick meconium	NL
11**	FOF/ labor pain	40w+2d	29	-	Room air	1	Azi/ ceftriaxone/ DiPhen	Good	NEG	NL
12**	FOF, cough	34w+6d	35	5	O2 with mask	10	H.Chl/ Azi/ ceftriaxone/ oseltamivir	Good	Severe preeclampsia	NL
13**	Diarrhea, FOF, cough	22w	31	10	O2 with mask	9	H.Chl/ Azi/ Kaletra/ oseltamivir/ ceftriaxone/ DiPhen	Good	NEG	NL
14**	labor pain	39w	36	3	O2 with mask	4	H.Chl/ Azi/ ceftriaxone	Good	NEG	NL
15**	FOF, cough	38w+1d	35	-	O2 with mask	4	H.Chl/ Azi/ oseltamivir	Good	NEG	NL
16**	Itching	37w+4d	23	5	Room air	3	H.Chl/ Azi/ cefazolin/ oseltamivir/	Good	cholestasis	NL
17**	FOF, cough, dyspnea	32w+4d	22	8	O2 with mask	8	H.Chl/ Azi/ oseltamivir/ ceftriaxone/ dextromethorphan	Good	NEG	NL
18**	FOF/ ROM	39w+6d	26	-	O2 with mask	1	azithromycin	Good	NEG	NL
19**	Fever chills, cough, dyspnea, fatigue	19w+4d	41	10	O2 with mask	5	H.Chl / oseltamivir	Good	NEG	NL
20**	FOF chills headache, myalgia	37w+1d	42	-	O2 with mask	4	H.Chl/ Kaletra/ Azi/ ceftriaxone/ vancomycin/ plasmapheresis/Tocolizomab/ Ribavirin	Good	NEG	NL

	Presenting complaints	GA	M Age	CT score	Respiratory Status	H p/day	Medical treatment	Mother status	Complication	Neonate status
21** *	FOF, cough, headache myalgia	15w+2d	35	-	-	-	H.Chl/ Azi/ Kaletra/ oseltamivir/	Good	NEG	NL
22** *	FOF chill, cough	23w+1d	19	-	-	-	Azi	Good	NEG	NL
23** *	Cough, nausea vomiting, myalgia	9w+1d	41	-	-	-	H.Chl	Good	NEG	NL
24** *	Myalgia	16w+1d	43	-	-	-	No treatment	Good	NEG	NL
25** *	FOF	27w+2d	25	-	-	-	No treatment	Good	NEG	NL
C-ICU Admission *			C-Ward admission**			outpatient ***				
Dx: diagnosis			MR: Maternal request			FOF: Feeling of fever			H.Chl: Hydroxychloroquine	
Azi: Azithromycin			DiPhen: Diphenhydramine			NL: Normal			GA: gestational age	

In 12 out of 20 admitted cases (44%), pregnancy terminated during hospitalization; 7 (58%) term pregnancies and 5 for obstetrical complications including fetal distress (28 W), IUFD (28 W), cholestasis (27 W), heart disease (34 W), and preterm labor (37 W). In this study, there were three maternal mortalities (12%) and overall low morbidity. Two patients died during the acute infection (in the C-ICU); both had twin pregnancies, a history of infertility, and died from cardiac arrest (one due to myocarditis). The third patient died due to hepatic failure five months after delivery.

Totally, there was 24 live birth from 23 mothers (1twin) and only two IUFD (twin). Thirteen neonates

(from 12 mothers) were born during hospitalization. Three out of 13 neonates (23%) expired, who were all preterm (27-28 W). PCR was taken from all the rest neonates with only one positive result. The infected neonate was isolated and showed no symptoms of COVID-19 infection after birth.

In the 6-month follow-up of women discharged from the hospital, there was no readmission due to COVID-19 infection. Nearly all signs and symptoms ameliorated during the first 2 weeks after discharge; however, the dyspnea in three patients and cardiac status in one patient improved more slowly. The pregnancy and disease outcomes are summarized in [Table 3](#).

Table 3. The pregnancy and disease outcome in 25 pregnant women diagnosed with COVID-19 infection

	Termination status				6-month follow up	
	Term	Preterm	Active phase	After remission	mother	neonate
Out patients (N=5)	5	0	0	5	All OK	All OK
C-Ward (N=15)	13	2	8	7	All OK	All OK
C-ICU (N=5)	1	4	5	0	3 dead	5 dead (2 twin, 2 IUFD, 1 RDS)

In the following section, the obstetric care and outcomes of the 5 pregnant women admitted to C-ICU are described in detail.

Case 1:

A 35-year-old patient G2P0Ab1 with twin pregnancy conceived through ICSI procedure at a gestational age

of 23w+3d. She complained of coughing, dyspnea, and feverishness. She had no past medical history. Her vital signs were normal, O₂ saturation=91%, and reached 94% with nasal flow O₂. Fetal well-being was assessed by NST and ultrasound. COVID-19 PCR was positive. Spiral lung and mediastinal CT scans showed patchy consolidation in both lungs, especially the left lower

lobe (LLL) (Figure 2). She was first admitted to C-Ward and treated by Oseltamivir, Ceftriaxone, Hydroxychloroquine, Kaletra, and oxygen therapy. After 24 hours, the patient's condition worsened, and her O₂ saturation dropped to 84%. She was admitted to the C-ICU. After 36 hours, she was intubated due to deterioration of her respiratory status (RR= 40 breaths/min, O₂ saturation = 65%).

The COVID-19 multidisciplinary team (including an anesthesiologist, perinatologist, infectious disease, C-ICU, and forensic medicine specialists) decided that termination of pregnancy would not improve the maternal condition. During C-ICU admission, she received 2 packed cells and a 3 day-trial of 20 mg/day intravenous immunoglobulin (IVIG). She was suspected of having hospital-acquired pneumonia; a combination of intravenous (IV) vancomycin and meropenem were started, while azithromycin and ceftriaxone were

tapered and then discontinued. The patient's general condition improved, and on the 13th day of hospitalization, she was extubated using a high-flow nasal cannula (HFNC). However, five days after extubation, the patient's condition deteriorated, resulting in re-intubation and mechanical ventilation. Echocardiography and chest X-ray demonstrated cardiomegaly and a modest decline in left ventricular ejection fraction (about 35%). Further imaging demonstrated an extensive involvement of the lung tissues with possible cardiogenic pulmonary edema. The laboratory tests deteriorated, especially hepatic tests and coagulation profiles. She received two units of fresh frozen plasma. Her pregnancy terminated spontaneously through vaginal delivery. Meanwhile, she developed episodes of refractory hypotension, and her ejection fraction declined to 10-15%. Unfortunately, the patient's general and hemodynamic status deteriorated, and she died of cardiac arrest.

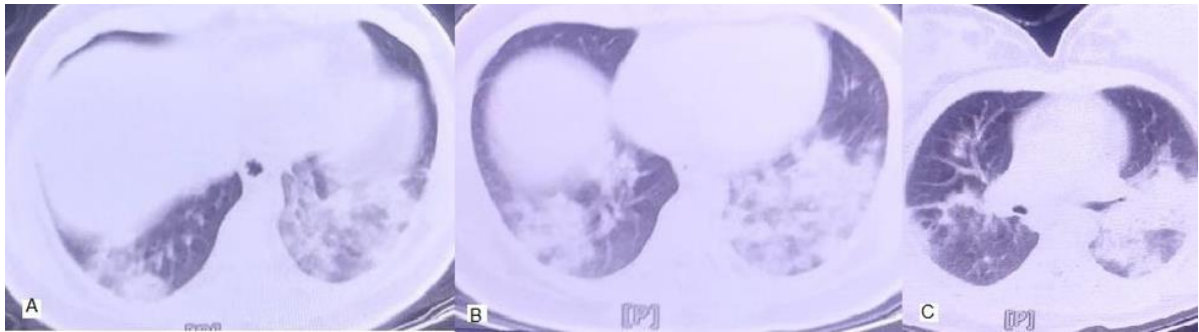


Figure 2. Patient no.1 CT scan images

Noncontrast chest CT scan showed diffuse alveolar opacities with consolidation and ground glass patterns in posterior aspects of lower lobes of both lungs, mostly compatible with viral pneumonia.

Case 2

A 48-year-old woman, G2P1 (previous vaginal live/delivery), with GA= 28w+2d, twin pregnancy (conceived through IVF procedure with donated egg) was referred to hospital. She complained of fever, chills, cough, and dyspnea, which started 3 days before her referral. She had no past medical history but had 3 previous surgeries, including appendectomy, abdominoplasty, and rhinoplasty. On admission, her vital signs were PR=110 bpm/min, T=38.8, RR=24, O₂ Sat=87% in room air, and 95% on supplemental oxygen. Laboratory findings were: AST=66 U/L, ALT=38U/L, LDH=908 U/L, ESR=60mm/hr, CRP=81.9mg/L. Her COVID-19 PCR test was positive. Initial treatment was with kaletra, hydroxychloroquine, tocilizumab, oseltamivir, prednisolone, vancomycin, meropenem, IVIG and oxygen. Unfortunately, after 2 days the patient's clinical condition worsened. Her RR=30 breath/min, T=39.5°C, and O₂ sat=60%, with associated fetal distress. The pregnancy terminated by emergency cesarean section and delivery of a live female infant (weighing 1210 grams), and a live male infant weighing 1300 grams. Both babies admitted in

neonatal C-ICU, and both babies tested negative for COVID-19. The mother was transported to C-ICU and extubated. Laboratory data improved: LFT = normal, LDH= 538 U/L, ESR = 6 mm/h and CRP =15mg/L. Unfortunately, severe respiratory distress occurred de novo and O₂ saturation decreased from 82% to 30-46%, requiring re-intubation. The platelet count decreased to 93,000. Liver and renal tests increased again (AST=291 U/L, ALT=75 U/L, Cr=1.67mg/dL, BUN=41mg/dL, INR>6, PTT>120sec, PT>60sec). Plasmapheresis was performed and finally, after 16 days of hospitalization the patient died of cardiac arrest. Both infants also died due to extensive DIC.

Case 3

A 25-year-old G1P0 with GA: 27w+6d and no past medical history presented dry cough, dyspnea, anorexia, and diarrhea that started 2 weeks before her referral. She also reported jaundice during the last few months. At the first visit, her vital signs were stable and O₂ saturation was 96% in room air, Hb=9.8g/dL, AST=37 U/L, ALT=30 U/L, Bili T=25 mg/dL, Bili D=15mg/dL, ALP=650U/L, LDH=750U/L, ESR=49-

mm/h, CRP=39mg/L, INR=2.4. In her last laboratory data (3 days before the referral), Bili T=20mg/dL, Bili D=13 mg/dL, ALP= 970U/L and ESR=55mm/h with normal LFT had been reported. The liver ultrasound was normal. She was treated with Azithromycin and Ursodeoxycholic acid (UDCA) and admitted to the C-ICU. Her COVID-19 PCR test was positive. Chest CT scan showed bilateral patchy ground-glass appearance, with more prominent consolidation in the lower and peripheral zones. An emergency C/S was performed due to cholestasis. A live female infant with an Apgar score of 8/10, weighing 1070 grams, was born and admitted to neonatal C-ICU due to prematurity and respiratory distress. The mother was treated with FFP, hydrocortisone, hydroxyzine, cefazolin, ceftriaxone, Kaletra, oseltamivir, hydroxychloroquine, N-acetyl cysteine (NAC), and metronidazole. The first day after C/S; the lab data showed: AST=37 U/L, ALT=63 U/L, ALP=619 U/L, LDH=1256 U/L, ESR=85 mm/hr, INR=2.93, Bili T=39.5 mg/dL, Bili D=18.9 mg/dL, with O₂ saturation declining to 80%. The liver increased in size, measured by ultrasound (130 mm). Liver biopsy showed parenchyma with prominent sinusoidal dilation, canalicular and centrilobular cholestasis (liver injury with predominantly cholestatic pattern), mild lobular inflammation, and hepatocytes anisonucleosis with ballooning degeneration (drug induced liver disease). As treatment continued, the patient's clinical condition and chest CT scan gradually improved. She was discharged from C-ICU after 10 days. She received azithromycin, hydroxychloroquine, ceftriaxone and meropenem in the C-Ward. After 8 days, she was discharged from the hospital with stable vital signs (O₂ saturation =93%, INR=1, ESR =26 mm/h, CRP=17 mg/L) and a prescription of rifampin, prednisolone, and hydroxychloroquine. This patient did not come back to the clinic for follow-up, and after contacting her family by telephone, it was discovered that the patient had been admitted to another center and

subsequently died 5 months after delivery due to hepatic failure.

Case 4

A 32-year-old lady G2P1 (previous live birth by cesarean section) with GA= 39w+1d presented dyspnea (which started one week previously), nasal congestion, sweating, cough, chest pain, sleep disorder, and otalgia. She had a past medical history of hypothyroidism (diagnosed 4 years ago), congenital achalasia (treated surgically), and ITP (from 13 years of age, requiring hydrocortisone injections 100 mg 3 times a day from 3 weeks before hospitalization). Her vital signs were: T=39.4°C, PR=104 bpm/min, RR=36 breath/min, O₂ saturation = 89% in room air and 91% with O₂ mask. Initial laboratory tests showed: WBC=10700, (Lymph=6%), PLT=58000, AST=70 U/L, ALT=91 U/L, ESR=18 mm/h and CRP=38.5 mg/L. She was the only patient amongst these 25 women whose COVID-19 PCR testing was negative, but her clinical presentation and chest CT scan findings supported a diagnosis of COVID-19 (Figure 3). Before her admission to C-ICU, her pregnancy was terminated by an emergency CS. A live female infant weighing 3800g with an Apgar score of 9/10 was born and her COVID-19 PCR testing was also negative. In C-ICU, she received hydroxychloroquine, Kaletra, ceftriaxone, and levothyroxine, 5 doses of interferon beta, 60 g IVIG, and prednisolone. Although ESR and CRP increased to 56 mm/h and 69 mg/L, respectively, the LFT decreased. After 9 days of hospitalization, the patient was discharged in a very good condition and ordered to self-quarantine at home for a further 5 days while receiving hydroxychloroquine. Most of her symptoms were resolved 10 days after the discharge. Both mother and baby are healthy after six months of follow-up.

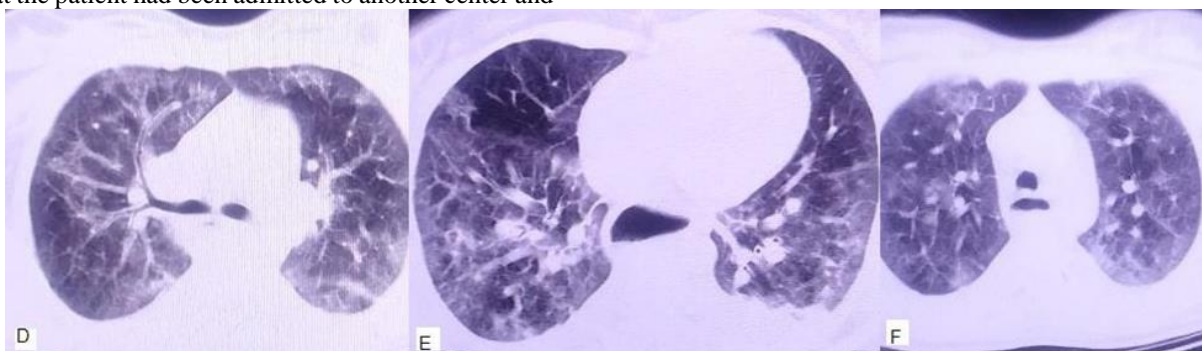


Figure 3. Patient no.4 CT scan images.

Noncontrast CT scan images revealed peripheral ground-glass opacities and crazy paving patterns associated with mosaic attenuation of lungs secondary to air trapping. These findings are highly suggestive of viral pneumonia.

Case 5

A 27-year-old woman, G1P0, with GA= 29w+6d, with a history of hypothyroidism during pregnancy, treated with levothyroxine, was referred to hospital. She complained of feeling feverish, rigors, sweating,

myalgia, productive cough, fatigue, conjunctivitis, dry mouth, sore throat, sneezing, nasal and throat itching, dyspnea, palpitations, anorexia, headache, dizziness, depression, nervousness, vomiting, flank pain, sleep

disorder and pruritus. Her COVID-19 PCR test was positive. Her vital signs were stable and laboratory tests were: WBC=7900, Lymph= 15%, Hb= 9.8 g/dL, PLT=214000, AST=15 U/L, ALT=20 U/L, ALP=575 U/L, LDH=634 U/L, Urea=18mg/dL, Cr=0.9 mg/dL, ESR=47 mm/h, CRP=16.3 mg/L. During her admission, she also had mild uterine contractions. Hydroxychloroquine, betamethasone, magnesium sulfate, and Indomethacin were commenced. After 6 days, she was transferred to the C-ICU due to severe dyspnea. Her contractions stopped after 1 day. Proteinuria (1386 grams) was detected in the 24-hour urine sample, and echocardiography showed severe eccentric mitral regurgitation (MR) to lateral wall, pulmonary artery pressure (PAP)= 58mmHg, mild left ventricle (LV) dilatation with dysfunction, raised LV filling, and pressure, with an ejection fraction (EF) of =25%. The patient was then admitted to the C-ICU. Due to severe dyspnea, the MDT suggested postponing delivery until 34 weeks of gestational age. Treatment for possible viral myocarditis (due to COVID-19 or peripartum cardiomyopathy) was initiated. She received digoxin, Isordil, and hydralazine. Finally, at 34 weeks of gestational age, CS was performed (due to maternal condition, threatened preterm labor, and breech presentation). A live male infant weighing 2410 grams was delivered, with an Apgar score of 9/10, and he was admitted to NICU. After delivery, the mother's respiratory function improved, and her cough stopped. She was transferred to C-Ward and then discharged from the hospital. The infant was also intubated due to respiratory distress, and after extubation, he had one seizure episode treated with phenobarbital. The baby had no further seizures after discontinuation of treatment and was ultimately discharged in a good general condition. After 6 months of follow-up, the ejection fraction showed a modest improvement to just 40%. The echocardiography (at 6 months) was as follows: Moderate LV systolic dysfunction, Apico-septal hypokinesia, NL left atrium (LA) and right atrium (RA) size, NL right ventricle (RV) function, mild to moderate MR, mild tricuspid regurgitation (TR), NL PAP at rest systolic pulmonary artery pressure SPAP= 30mmHg, EF=40%). Clinically, the mother and baby remain in good condition.

Discussion

In this case series, we reported 25 COVID-19 infected pregnant women with positive signs, symptoms, and positive PCR testing in 24 out of 25.

In our report, the symptoms, signs, lab data of infected pregnant women were similar to the other reports. Fever, cough, dyspnea as the predominant symptoms (11, 16, 17), the decreased oxygen saturation <95%, tachycardia, fever (45%) (16-19) as the most significant signs, and high CRP level as the most common abnormal laboratory data are revealed (2, 18). The most common finding on the Chest CT scan of 13 patients was a ground-glass appearance,

which was similar to other data (8-10, 19). As expected, the trend of CT severity score was associated with disease severity, C-ICU hospitalization, and intubation.

Among these 25 pregnant women, the vertical transmission was very low (one out of 23 live neonates). Some other studies confirmed the rare vertical transmission (11-12, 20).

Similar to some other published articles (21-23), the maternal mortality rate in our report was 12% (3 out of 25), all preterm (23-28 weeks). Two of the expired mothers had twin pregnancies. This could be explained by the fact that all possible effects of the virus on host cells and vice versa, which deteriorate normal organ function, could get worst in pregnant women and that the immunological changes during pregnancy increase susceptibility to viral infections, in particular respiratory pathogens (24-26). Consequently, pregnant women are more intolerant to hypoxia, especially in twin pregnancy and in early third trimester when maximum cardiac output happens and make the mother more prone to develop severe pneumonia, which is predisposing to hypoxemic respiratory failure due to COVID-19 pneumonia.

Conclusion

In this case series, among 25 women with confirmed COVID-19, maternal, fetal, and neonatal mortality happened mostly in the early third trimester and in twin pregnancy.

Acknowledgments

This study was funded and supported by the Preventative Gynecology Research Center, Shahid Beheshti University of Medical Sciences, Tehran, Iran.

Author's Contributions

MS: supervision, collected the data. FF: Conceived and designed the analysis, drafting and revising the manuscripts in English. MM: wrote the paper contributed data or analysis tools. SMA, LA, SS, TJ, PP, SA, MY, BN, SZ, SH, MH, MMM, SPS, AM, DA: collected the data. TV: Contributed data or analysis tools; performed the analysis.

Conflict of Interest

The authors declared no conflict of interest.

Availability of Data and Materials

The data set collected and analyzed during the current study is available from the corresponding author on reasonable request.

Ethics Approval

This study was approved by the Ethics Committee of Shahid Beheshti University of Medical Sciences (IR.SBMU.RESEARCH.REC.1399.766).

Consent to Participate

Informed consent was obtained from all individual participants included in the study.

Consent for Publication

Not applicable.

References

- Lu S, Lin J, Zhang Z, Xiao L, Jiang Z, Chen J, Hu C, Luo S. Alert for non-respiratory symptoms of coronavirus disease 2019 patients in epidemic period: A case report of familial cluster with three asymptomatic COVID-19 patients. *J Med Virol*. 2021;93(1):518-21. [DOI:10.1002/jmv.25776] [PMID]
- Zeng JH, Liu YX, Yuan J, Wang FX, Wu WB, Li JX, et al. First case of COVID-19 complicated with fulminant myocarditis: a case report and insights. *Infection*. 2020;48(5):773-7. [PMCID] [DOI:10.1007/s15010-020-01424-5] [PMID]
- Chan JF, Yuan S, Kok KH, To KK, Chu H, Yang J, et al. A familial cluster of pneumonia associated with the 2019 novel coronavirus indicating person-to-person transmission: a study of a family cluster. *Lancet*. 2020;395(10223):514-23. [DOI:10.1016/S0140-6736(20)30154-9]
- Han C, Duan C, Zhang S, Spiegel B, Shi H, Wang W, Zhang L, Lin R, Liu J, Ding Z, Hou X. Digestive symptoms in COVID-19 patients with mild disease severity: clinical presentation, stool viral RNA testing, and outcomes. *Am J Gastroenterol*. 2020; 115(6):916-23. [PMCID] [DOI:10.14309/ajg.0000000000000664] [PMID]
- Puntmann VO, Carerj ML, Wieters I, Fahim M, Arendt C, Hoffmann J, et al. Outcomes of cardiovascular magnetic resonance imaging in patients recently recovered from coronavirus disease 2019 (COVID-19). *JAMA Cardiol*. 2020;5(11):1265-73. [PMCID] [DOI:10.1001/jamacardio.2020.3557] [PMID]
- Huang L, Zhao P, Tang D, Zhu T, Han R, Zhan C, et al. Cardiac involvement in patients recovered from COVID-2019 identified using magnetic resonance imaging. *Cardiovasc Imag*. 2020;13(11):2330-9. [PMCID] [DOI:10.1016/j.jcmg.2020.05.004] [PMID]
- Ai T, Yang Z, Hou H, Zhan C, Chen C, Lv W, et al. Correlation of chest CT and RT-PCR testing for coronavirus disease 2019 (COVID-19) in China: a report of 1014 cases. *Radiology*. 2020;296(2):E32-40. [DOI:10.1148/radiol.2020200642] [PMID]
- Liu D, Li L, Wu X, Zheng D, Wang J, Yang L, et al. Pregnancy and Perinatal Outcomes of Women With Coronavirus Disease (COVID-19) Pneumonia: A Preliminary Analysis. *AJR Am J Roentgenol*. 2020;215(1):127-32. [DOI:10.2214/AJR.20.23072] [PMID]
- Liu H, Liu F, Li J, Zhang T, Wang D, Lan W. Clinical and CT imaging features of the COVID-19 pneumonia: Focus on pregnant women and children. *J Infect*. 2020;80(5):e7-13. [PMCID] [DOI:10.1016/j.jinf.2020.03.007] [PMID]
- Long C, Xu H, Shen Q, Zhang X, Fan B, Wang C, et al. Diagnosis of the Coronavirus disease (COVID-19): rRT-PCR or CT?. *Eur J Radiol*. 2020;126:108961. [DOI:10.1016/j.ejrad.2020.108961] [PMID]
- Chen H, Guo J, Wang C, Luo F, Yu X, Zhang W, et al. Clinical characteristics and intrauterine vertical transmission potential of COVID-19 infection in nine pregnant women: a retrospective review of medical records. *Lancet*. 2020;395(10226):809-15. [DOI:10.1016/S0140-6736(20)30360-3]
- Liu W, Wang Q, Zhang Q, Chen L, Chen J, Zhang B, et al. Coronavirus disease 2019 (COVID-19) during pregnancy: a case series.
- Yu N, Li W, Kang Q, Xiong Z, Wang S, Lin X, Liu Y, Xiao J, Liu H, Deng D, Chen S. Clinical features and obstetric and neonatal outcomes of pregnant patients with COVID-19 in Wuhan, China: a retrospective, single-centre, descriptive study. *Lancet Infect Dis*. 2020;20(5):559-64. [DOI:10.1016/S1473-3099(20)30176-6]
- Schwartz DA. An analysis of 38 pregnant women with COVID-19, their newborn infants, and maternal-fetal transmission of SARS-CoV-2: maternal coronavirus infections and pregnancy outcomes. *Arch Pathol Lab Med*. 2020;144(7):799-805. [DOI:10.5858/arpa.2020-0901-SA] [PMID]

15. World Health Organization. Clinical management of severe acute respiratory infection (SARI) when COVID-19 disease is suspected: interim guidance, 13 March 2020. World Health Organization; 2020. [DOI:10.15557/PiMR.2020.0003]
16. Dashraath P, Wong JL, Lim MX, Lim LM, Li S, Biswas A, et al. Coronavirus disease 2019 (COVID-19) pandemic and pregnancy. *Am J Obstet Gynecol.* 2020;222(6):521-31. [PMCID] [DOI:10.1016/j.ajog.2020.03.021] [PMID]
17. Zhu H, Wang L, Fang C, Peng S, Zhang L, Chang G, et al. Clinical analysis of 10 neonates born to mothers with 2019-nCoV pneumonia. *Transl Pediatr.* 2020;9(1):51. [DOI:10.21037/tp.2020.02.06] [PMID] [PMCID]
18. de Souza Santos D, de Oliveira Menezes M, Andreucci CB, Nakamura-Pereira M, Knobel R, et al. Disproportionate impact of coronavirus disease 2019 (COVID-19) among pregnant and postpartum black women in Brazil through structural racism lens. *Clin Infect Dis.* 2021;72(11):2068-9. [DOI:10.1093/cid/ciaa1066] [PMID] [PMCID]
19. Zaigham M, Andersson O. Maternal and perinatal outcomes with COVID-19: a systematic review of 108 pregnancies. *Acta Obstet Gynecol Scand.* 2020;99(7):823-9.
20. Ashraf MA, Keshavarz P, Hosseinpour P, Erfani A, Roshanshad A, Pourdast A, et al. Coronavirus disease 2019 (COVID-19): a systematic review of pregnancy and the possibility of vertical transmission. *J Reprod Infertil.* 2020;21(3):157.
21. Blitz MJ, Rochelson B, Minkoff H, Meiorowitz N, Prasannan L, London V, et al. Maternal mortality among women with coronavirus disease 2019 admitted to the intensive care unit. *Am J Obstet Gynecol.* 2020;223(4):595-9. [PMCID] [DOI:10.1016/j.ajog.2020.06.020] [PMID]
22. Cheng SO, Khan S, Alsafi Z. Maternal death in pregnancy due to COVID-19. *Ultrasound Obstet Gynecol.* 2020;56(1):122. [DOI:10.1002/uog.22111] [PMID] [PMCID]
23. Hantoushzadeh S, Shamshirsaz AA, Aleyasin A, Seferovic MD, Aski SK, et al. Maternal death due to COVID-19. *Am J Obstetrics Gynecol.* 2020;223(1):109-e1. [PMCID] [DOI:10.1016/j.ajog.2020.04.030] [PMID]
24. Takemoto ML, Menezes MO, Andreucci CB, Knobel R, Sousa LA, Katz L, et al. Maternal mortality and COVID-19. *J Matern Fetal Neonatal Med.* 2020:1-7. [DOI:10.1080/14767058.2020.1786056] [PMID]
25. Reinhard G, Noll A, Schlebusch H, Mallmann P, Ruecker AV. Shifts in the TH1/TH2 balance during human pregnancy correlate with apoptotic changes. *Biochem Biophys Res Commun.* 1998;245(3):933-8. [DOI:10.1006/bbrc.1998.8549] [PMID]
26. Gujski M, Humeniuk E, Bojar I. Current state of knowledge about SARS-CoV-2 and COVID-19 disease in pregnant women. *Med Sci Monit.* 2020;26:e924725-1. [DOI:10.12659/MSM.924725]

How to Cite This Article:

Hosseini M, Farzaneh F, Mirhadi M, Mahdavi Anari S A A, Ajori L, Salehpour S, et al et al . COVID-19 Infection in Iranian Pregnant Women: A Case Series of 25 Patients. *J Obstet Gynecol Cancer Res.* 2022; 7(4):286-95.

Download citation:

[BibTeX](#) | [RIS](#) | [EndNote](#) | [Medlars](#) | [ProCite](#) | [Reference Manager](#) | [RefWorks](#)