

Successful Pregnancy after Conservative Surgical Management of Uterine Rupture due to Gestational Trophoblastic Neoplasia: A Case Report

Fariba Yarandi¹, Sara Ramhormozian², Behzad Asanjarani³, Elham Shirali^{1*}

1. Department of Obstetrics and Gynecology, Yas Hospital, School of Medicine, Tehran University of Medical Sciences, Tehran, Iran
2. Department of Obstetrics and Gynecology Surgery, Yas Hospital, School of Medicine, Tehran University of Medical Sciences, Tehran, Iran
3. Department of Internal Medicine, School of Medicine, Amir Alam Hospital, Tehran University of Medical Sciences, Tehran, Iran



Article Info

[10.30699/jogcr.7.5.458](https://doi.org/10.30699/jogcr.7.5.458)

Received: 2021/07/11;

Accepted: 2021/11/10;

Published Online: 07 July 2022;

Use your device to scan and read the article online



Corresponding Information:

Elham Shirali,
Department of Obstetrics and Gynecology,
Yas Hospital, School of Medicine, Tehran
University of Medical Sciences, Tehran, Iran
Email: Eshirali@sina.tums.ac.ir



Copyright © 2022, This is an original open-access article distributed under the terms of the Creative Commons Attribution-noncommercial 4.0 International License which permits copy and redistribution of the material just in noncommercial usages with proper citation.

ABSTRACT

GTN (Gestational trophoblastic neoplasm) complications such as uterine rupture or massive bleeding can be life-threatening and usually need a hysterectomy. In young patients who want to preserve fertility, hysterectomy is not suitable. Under specific circumstances, some physicians choose conservative management. Uterine preservation after complicated GTN is rare by itself. This study presents a 26-year-old woman who developed uterine rupture and massive intraperitoneal bleeding under chemotherapy for GTN. The patient strongly desired her fertility to be preserved; thus, conservative surgical management was done, and the patient could become pregnant in upcoming years.

In conclusion, conservative management of GTN patients who develop high-risk complications and desire for future pregnancies must be considered an option. In published case reports, outcomes of conservative surgical management have been very good if managed properly.

Keywords: Gestational trophoblastic neoplasia, Hysterectomy, Massive bleeding, Uterine rupture, Conservative surgery

Introduction

Gestational trophoblastic disease (GTN) is a group of tumors that present as serious and uncommon pregnancy complications. This group includes different types of tumors developed due to the impaired proliferation of trophoblastic tissues, including epithelioid trophoblastic tumors, placental-site trophoblastic tumors, choriocarcinoma, and other tumors arising from hydatidiform moles (1). The diagnosis of GTN is made according to FIGO (Federation of Gynecology and Obstetrics) criteria based on clinical and histopathologic features (2). Nearly half of GTN cases are detected after hydatidiform moles (3). An invasive mole is a form of GTN which involves myometrium and vascular structures, which could also involve extrauterine structures concurrently. Invasive moles resemble choriocarcinomas, but they are distinguished by the presence of hydropic villi along with the obvious trophoblastic proliferation. Myometrial invasion of invasive mole can manifest as severe complications such as intraabdominal hemorrhage or uterine rupture.

These complications can be potentially life-threatening and usually result in hysterectomy (4). Overall, surgical intervention is widely used in managing cases with GTN, especially in patients who show complications. In young patients who want to get pregnant in the future, hysterectomy is not preferred. Thus, some physicians have chosen conservative management under specific circumstances defined by resecting the localized ruptured lesion and primary repair over hysterectomy. Overall, fertility preservation after complicated GTN cases is rarely reported in the literature. This study presents a 26-year-old woman with successful pregnancy after a previous uterine rupture due to GTN treated conservatively.

Case Report

Case

The case we present is a 26-year-old woman with a previous history of a cesarean section due to breech presentation 5 years before. The patient had a missed

abortion in the 8th week of pregnancy and was presented to the hospital due to massive bleeding. She underwent emergent dilatation and curettage, and the histopathological examination revealed a partial hydatiform mole. The patient was then followed up with the diagnosis of molar pregnancy. In the follow-up course, B-hcg became plateau and then rised. Thus, the patient was admitted for further diagnostic workup 6 weeks. Ultrasonography showed a hypervascular heterogeneous area 4 centimeters in maximal dimension, in the posterior myometrium suggesting an invasive mole (Figure 1). The baseline B-hCG was 48000 mIU/mL, and stage 1 GTN (based on FIGO staging) was diagnosed. The patient had low score based on risk score criteria developed by the World Health Organization (WHO) as used by FIGO. Treatment was initiated with single-agent chemotherapy (Dactinomycin). After receiving 4 doses of Dactinomycin (at 2-week intervals), the patient was referred to the hospital with abdominal pain and hemodynamic instability.

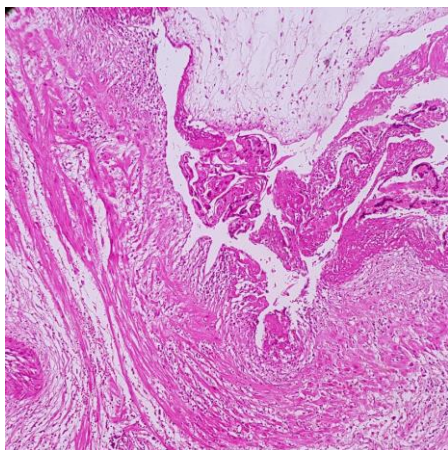


Figure 1. The histological image of the patient's invasive mole is shown here

Bedside evaluations with ultrasonography in Emergency Ward revealed uterine rupture and massive hemoperitoneum. The patient was sent emergently to the operating room with a B-hCG of 28000 mIU/mL and a hemoglobin level of 4.8 mg/dL. Administration of packed red blood cells was initiated at the beginning of surgery. Uterine rupture measuring 3 cm at right cornua with the expulsion of GTN products was evident. Right cornuectomy and salpingectomy were conducted, and corneal repair was performed in two layers with vicryl sutures 1-0. After maintenance of hemostasis and washing of the abdominal cavity, the surgery was finished. Overall, 4 units of packed red blood cells were used, and hemoglobin was raised to 9 mg/dL afterward.

The patient underwent treatment with an EMA-CO regimen with a standard dose as soon as possible after surgery (Table 1). B-hCG concentration at the beginning of chemotherapy was 9500 mIU/ml. After 3 cycles of treatment with the EMA-CO regimen, B-hCG became negative. Three additional cycles of EMA-CO were administered as consolidation treatment. For the follow-up, the patient underwent monthly B-hCG measurement. Due to the absence of disease recurrence, the patient was permitted for pregnancy after 12 months. The patient became pregnant three years later. Her prenatal care was done under control in our center without any complication. She was scheduled for elective cesarean section at 37 weeks of pregnancy. The baby was a girl with a cephalic presentation, appropriate Apgar score, and normal appearance. Cesarean section was conducted with Pfannenstiel skin incision and the low transverse incision at the lower segment of the uterus. During the surgery, complete healing of repaired cornual region with no signs of dehiscence was seen.

Table 1. EMA-CO chemotherapy regimen

Day 1	
-	Actinomycin D: 0.5 mg IV bolus
-	Etoposide: 100 mg/m ² IV/500 cc N/S (30 minutes)
-	Methotrexate: 100 mg/m ² , IV/push slowly
-	Methotrexate: 200 mg/m ² , IV/500 cc DW5% (12 hours)
Day 2	
-	Actinomycin D: 0.5 mg IV bolus
-	Etoposide: 100 mg/m ² IV/500 cc N/S (30 minutes)
-	Folinic acid: 15 mg IM/BD/48 hours
Day 8	
-	Vincristine: 1 mg/m ² IV bolus (maximum: 2 mg)
-	Cyclophosphamid: 600 mg/m ² IV/500 cc N/S (30 minutes)

Discussion

In this article, we presented a case of uterine rupture in the setting of GTN, which was treated conservatively and led to a successful pregnancy subsequently. Conservative surgical management in similar scenarios is rare, and most surgeons perform hysterectomies under these circumstances. Uterine preservation is not preferred in these cases by many surgeons because of the risk of uterine rupture and other complications in the next pregnancies. The dilemma emerges in young patients who desire to preserve their fertility and become pregnant in the future. Hysterectomy should be avoided in these cases if possible. To preserve fertility in these high-risk patients, efforts must be made to repair the uterus and monitor the patient closely to ensure GTN eradication and the absence of recurrence. In our experience, resection of the lesion, primary repair of the uterus, and subsequent chemotherapy could lead to complete resolution in addition to uterine preservation. Fortunately, our patient became pregnant years after surgery and had an uncomplicated pregnancy and labor with a healthy child. Thus, in such cases, a hysterectomy must be seen as the choice and only treatment available; other treatment options must also be considered when encountering these risky conditions, particularly in young patients desiring to preserve their fertility.

Several case reports exist in the literature describing fertility-preserving surgeries in complicated GTN cases. Behtash *et al.* (5) reported two young patients receiving chemotherapy due to GTN. Under chemotherapy, they developed acute abdominal shock. In the laparotomy, localized uterine resection and primary repair was performed. Both patients had successful pregnancies in the upcoming years. Rojas-Espailat *et al.* (6) reported a case with GTN, which was resistant to chemotherapy. The patient insisted on the preservation of her fertility. Thus, it was decided to excise lesions locally and continue treatment with chemotherapy agents. The patient outcome was excellent, with resolution of residual disease and the ability to become pregnant (start next paragraph with this sentence). Estrella *et al.* (7) reported two cases of uterine rupture in the context of GTN.

Similarly, these two patients were young with a desire for pregnancy. They were managed with primary uterine rupture repair by hemostatic stitches and postoperative chemotherapy. They were completely cured with the preservation of fertility potential. That study suggests that conservative surgical approaches must be considered in patients with uterine rupture who

desire pregnancy and have small rupture extents. Another report by Tjalma *et al.* (8) has described a patient with chemo-resistant GTN who was treated with local resection of the tumor, which led to complete resolution of the disease and absence of recurrence in the next years. Case *et al.* (9) reported a woman with chemo-resistant GTN treated with localized resection of the tumor and uterine reconstruction. The patient experienced two uncomplicated pregnancies and deliveries years after surgery. Hasanzadeh *et al.* (10) reported four cases of fertility preservation surgeries in the setting of GTN. Two cases developed shock and abdominal pain under chemotherapy, and two other cases were resistant to chemotherapy or showed complications due to chemotherapy. All these patients were treated with conservative surgical management, and all patients went into the remission phase. One patient became pregnant with normal pregnancy and delivery course. Zamani *et al.* (11) reported fertility preservation surgery in patients with an invasive mole and subsequent hemoperitoneum. They evacuated the hemoperitoneum and then resected a mass in the posterior wall of the uterus. Uterine was preserved, and the patient became disease-free and normal in the follow-up. Likewise, David-West *et al.* (12) also reported a case with a low-risk GTN who developed massive hemoperitoneum, which was successfully managed with conservative surgery.

Conclusion

In conclusion, as in our experience and reports from the authors worldwide, conservative management of GTN patients who develop high-risk complications and desire for future pregnancies must be considered an option. Hysterectomy in such cases can be highly undesired and maybe a huge burden for them. In published case reports, outcomes of conservative surgical management have been outstanding if appropriately managed.

Acknowledgments

The authors would like to thank the Firoozgar clinical Research development Center, Firoozgar Medical Center, Iran University of Medical Sciences, Tehran, Iran.

Conflict of Interest

The authors declared no conflicts of interest.

References

- Shih I-M. Gestational trophoblastic neoplasia-pathogenesis and potential therapeutic targets. *Lancet Oncol.* 2007;8(7):642-50. [DOI:10.1016/S1470-2045(07)70204-8]
- Ngan HYS, Seckl MJ, Berkowitz RS, Xiang Y, Golfier F, Sekharan PK, et al. Update on the diagnosis and management of gestational trophoblastic disease. *Int J Gynaecol Obstet.* 2018;143:79-85. [DOI:10.1002/ijgo.12615] [PMID]
- Morgan JM, Lurain JR. Gestational trophoblastic neoplasia: an update. *Curr Oncol Rep.* 2008;10(6):497-504. [DOI:10.1007/s11912-008-0075-y] [PMID]
- Goldstein DP, Berkowitz RS. Current management of gestational trophoblastic neoplasia. *Hematol Oncol.* 2012;26(1):111-31. [DOI:10.1016/j.hoc.2011.10.007] [PMID]
- Behtash N, Ansari S, Sarvi F. Successful pregnancy after localized resection of perforated uterus in choriocarcinoma and a literature review. *Int J Gynecol Cancer.* 2006;16(Suppl 1). [DOI:10.1136/ijgc-00009577-200602001-00084] [PMID]
- Rojas-Espallat L, Houck KL, Hernandez E, Berkowitz RS. Fertility-sparing surgery for persistent gestational trophoblastic neoplasia in the myometrium: a case report. *J Reprod Med.* 2007;52(5):431-4.
- Estrella J, Soriano-Estrella A. Conservative management of uterine rupture in gestational trophoblastic neoplasia: a report of 2 cases. *Int J Gynecol Cancer.* 2009(19):1666-70. [DOI:10.1111/IGC.0b013e3181a84252] [PMID]
- Tjalma WAA, Vermorken JB. The role of hysterotomy in the management of gestational trophoblastic neoplasia. *Int J Gynecol Cancer.* 2006;16(2). [DOI:10.1111/j.1525-1438.2006.00585.x] [PMID]
- Case AM, Wilson S, Colgan TJ, Greenblatt EM. Fertility-sparing surgery, with subsequent pregnancy, in persistent gestational trophoblastic neoplasia: case report. *Hum Reprod.* 2001;16(2):360-4. [DOI:10.1093/humrep/16.2.360] [PMID]
- Hasanzadeh M, VahidRoodsari F, Ahmadi S, GavedanMehri M, Azadeh T. Fertility sparing surgery in gestational trophoblastic neoplasia: A report of 4 cases. *Int J Reprod Biomed.* 2016;14(9):603-6. [DOI:10.29252/ijrm.14.9.603] [PMID] [PMCID]
- Zamani M, Alizadeh S, Mollabashi M. Fertility-sparing uterine lesion resection in a woman with hemoperitoneum due to invasive mole: A rare case report [published online ahead of print, 2021 Jun 18]. *Int J Surg Case Rep.* 2021(106117). [DOI:10.1016/j.ijscr.2021.106117] [PMID] [PMCID]
- David-West G, Jeganathan S, Cohen N, Maddineni S, Friedman B, Cohen S. Conservative management of uterine rupture in gestational trophoblastic neoplasia. *Gynecol Oncol Rep.* 2020;32. [PMCID] [DOI:10.1016/j.gore.2020.100539] [PMID]

How to Cite This Article:

Yarandi F, Ramhormozian S, Asanjarani B, Shirali E. Successful Pregnancy after Conservative Surgical Management of Uterine Rupture due to Gestational Trophoblastic Neoplasia: A Case Report. *J Obstet Gynecol Cancer Res.* 2022; 7(5):458-61.

Download citation:

[BibTeX](#) | [RIS](#) | [EndNote](#) | [Medlars](#) | [ProCite](#) | [Reference Manager](#) | [RefWorks](#)