

A Rare Case of Primary Tubo-Ovarian Hydatid Cyst, Approved Pathologically and Molecularly

Nahid Ghanbarzadeh¹ , Ali Nadjfai-Semnani² , Mohammad Nadjafi-Semnani³ ,
Mahmoodreza Behravan⁴ , Majid Zare-Bidaki^{4*} 

1. Department of Gynecology and Obstetrics, Birjand University of Medical Sciences, Birjand, Iran
2. Department of General Surgery, Zahedan University of Medical Sciences, Zahedan, Iran
3. Department of Urology, Birjand University of Medical Sciences, Birjand, Iran
4. Infectious Diseases Research Center, Birjand University of Medical Sciences, Birjand, Iran



Article Info

 [10.30699/jogcr.8.2.184](https://doi.org/10.30699/jogcr.8.2.184)

Received: 2022/08/08;

Accepted: 2022/12/17;

Published Online: 22 Feb 2023;

Use your device to scan and read the article online



Corresponding Information:

Majid Zare-Bidaki,

Infectious Diseases Research Center, Birjand
University of Medical Sciences, Birjand, Iran

Email: med.parasitol@gmail.com

ABSTRACT

Echinococcus granulosus (sensu lato) is the main cause of Cystic hydatid in human and livestock in the world and is considered a neglected tropical disease. Hydatid cysts often form in the liver (50–70%) and less frequently the lung, spleen, kidney, bone, brain and genital system. Ovarian hydatid cyst is one of the rarest cases with nonspecific clinical presentation. Here in a case report study, we report a primary unilateral ovarian hydatid cyst in a 45-years-old woman. This patient was presented with a large pelvic mass. A pelvic multiloculated mass in abdominal ultrasound and a solid-cystic lesion of the left adnexa in CT scan were reported. All other laboratory tests and chest X-ray showed typical results. Molecular method was performed to confirm radiography and staining methods. A cystic mass on the left fallopian tube and ovary was found in the patient's laparotomy and all were resected with the appearance of a tubo-ovarian abscess. Postoperative pathological and molecular diagnosis confirmed a hydatid cyst disease. Five years of follow-up revealed no recurrence of the disease. Hydatid cyst can.

Keywords: Ovary, Hydatid Cyst, Birjand, *Echinococcus granulosus*, Case Report



Copyright © 2023, This is an original open-access article distributed under the terms of the Creative Commons Attribution-noncommercial 4.0 International License which permits copy and redistribution of the material just in noncommercial usages with proper citation.

Introduction

Hydatid cyst is one of the most common diseases of zoonosis. The way to transmit the infection is to eat contaminated water and food with parasite eggs or contact with infected animal. In humans *Echinococcus granulosus* is the most common cause of hydatid cyst disease which is a rare parasitic infection, primarily involving the liver and lungs in about 29–65% and 25–48% of cases, respectively and also cysts can form in the bones, spleen, heart, brain and kidney (1, 2). Some sporadic cases may develop the primary hydatid cyst disease in the tubo-ovarian and retroperitoneal space (3, 4). According to the latest results, the pooled prevalence of hydatid cyst in Iran was estimated at 5% [95% CI: 3-6%] (5). The disease may have an asymptomatic period of several years until the onset of some complications, such as rupture of the cyst, pressure on the surrounding tissues and so on. The involved organ and also the number and size of cysts lead to a variety of symptoms (6), which may result in

high-risk situations and severe complications with high mortality rate could have consequences such as anaphylactic shock caused by cyst rupture during surgery (7). The ovary is a highly organized composite of germ cells (oocytes) and somatic cells whose interactions dictate formation of oocyte-containing follicles, development of both oocytes and somatic cells, ovulation, and formation of the corpus luteum and can have various diseases (8, 9). Here, we present a case with primary tubo-ovarian hydatid disease from a nonendemic region.

Case Presentation

In a case report study, a 45-years-old female, resident of a rural area of Southern Khorasan province of Iran, was admitted with a six-month dull abdominal pain following irregular menstruation and metrorrhagia

over one year. She was engaged in farming and animal husbandry. She had five full-term pregnancies and used oral contraceptives.

A large pelvic mass, inseparable from uterus and adnexa, was palpated on physical examination. An abdominal ultrasound assessment revealed a pelvic multiloculated 130 mm mass, suggesting a left tubo-ovarian tumor. Other organs were healthy in the ultrasound report. Computed tomogram (CT) scan of the abdomen showed a 120 by 52 mm solid-cystic

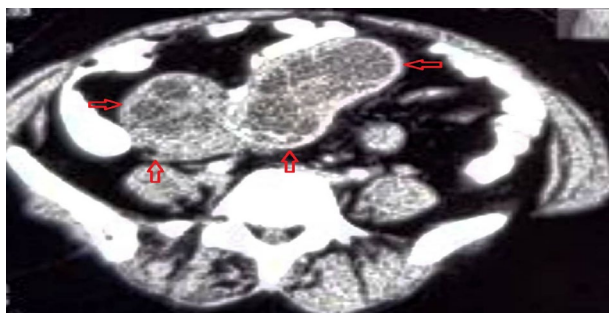


Figure 1. Involvement of left adnexa in CT scan imaging

Postoperative pathological diagnosis confirmed a hydatid disease (Figure. 3). The patient was closely monitored postoperatively. There was no abnormality in CT scans of the abdomen, pelvic cavity, head, and lung four days after the surgery. The patient was discharged five days after the operation, with no adverse clinical signs. Oral administration of Albendazole was continued for 14 days. No recurrence was observed in this patient after five years. Eventually, molecular method was performed to confirm radiography and pathological diagnosis. The

lesion in the left adnexa, which was hypo- to hyperdense with peripheral contrast enhancement (Figure. 1). Preoperative routine laboratory tests and chest radiographs showed normal results. Also, all tumor markers were negative. The patient underwent laparotomy with left adnexectomy, peritoneal cytology, and biopsies. No ascites was noted at operation, and other abdominal and pelvic organs were normal. The left fallopian tube and ovary were found as a cystic mass and were resected with the appearance of a tubo-ovarian abscess (Figure. 2).

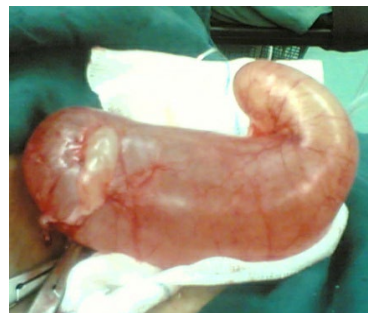

Figure 2. Macroscopic appearance of primary tubo-ovarian hydatid cyst

tissue DNA genomic DNA extraction mini kit (Favorgen, Taiwan) was used to extract DNA according to the manufacturer's instruction. The mitochondrial COX-1 gene were amplified from the germinal layer extracted DNA. The primer pairs JB3 (5'-TTTTTGGGCATCCTGAGGTTTAT-3') and JB4.5 (5' TAAAGAAAGAACATAATGAAAATG-3') were used to amplify a 420 bp fragment. Amplification of the cox1 genes was performed using PCR thermocycler.

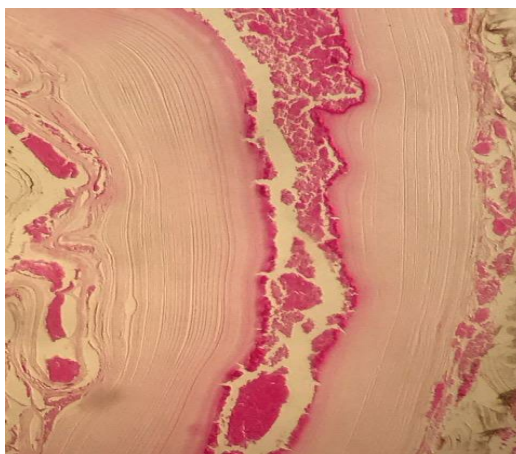


Figure 3. Hydatid cyst layers with abundant eosinophils
H & E staining, magnification $\times 400$

Discussion

Ovarian hydatid cyst has been reported from different areas including Africa (Ethiopia and Tunisia) (10, 11), Western Asia (Saudi Arabia) (12), and

Southern Asia (India) (13). There are several studies of the tubo-ovarian hydatid cyst in the average age range of 50 (range: 34-84) years in Iran (14-16). The majority of reported cases were bilateral tubo-ovarian hydatid cyst. There are sporadic reported cases of isolated

hydatid cyst of the fallopian tube (17, 18). These rare reports represent a low incidence of primary tubo-ovarian hydatidosis, which may lead to the suggestion of hydatid cyst due to *E. granulosus* as the differential diagnosis of multicystic tubo-ovarian lesions among suspicious patients in endemic areas (19).

This case is a pure primary hydatid infection of the ovary from Iran. The diagnosis was made after laparotomy for the evaluation of the cause of the symptoms. However, the most popular methods of diagnosis are ultrasound, CT scan, and MRI. Imaging methods are much more sensitive than immunological tests (15). A high frequency (7.5 MHz) transvaginal ultrasound has been suggested as a useful tool for the detection of tubo-ovarian hydatid cysts (10).

Moreover, CT and MRI methods are used in the diagnosis of these cysts. Chest x-ray imaging is a useful tool for the detection of associated pulmonary hydatid cyst (20). Hydatid cyst may be suspected by gynecologist, radiologist, and histopathologist when a septated cystic pelvic mass is found in these imaging methods (12).

Conclusion

Hydatid cyst disease is still considered a public health problem in Iran. Primary tubo-ovarian involvement is a rare disease with fortuitous discovery,

and its non-specific clinical presentation leads to the difficulty of the diagnosis. However, the ultrasound method, particularly high-frequency vaginal sonography, is suggested the method of choice to make a precise diagnosis and total resection of the lesions is the treatment of choice of primary tubo-ovarian hydatid disease. Molecular methods are suggested to confirm pathological and radiographic diagnosis.

Acknowledgments

The authors would like to thank the staff of Valiasr Hospital in Birjand city, Iran. The authors declare that there is no conflict of interest.

Conflict of Interest

The authors declared no conflict of interest.

Authors' contributions

N.Gh. and M.N.S. participated in collection of patient specimens. A.N.S. participated in evaluation of patient specimens. MR.B. participated in pathology and molecular tests of the study. M.Z.B. participated in critical analysis of the data and drafting the manuscript. All authors reviewed and approved the final manuscript.

References

1. Matini M, Roostaei M, Fallah M, Maghsood AH, Saidijam M, Harandi MF. Genetic identification of *Echinococcus granulosus* isolates in Hamadan, Western Iran. *Iran J Parasitol*. 2018;13(3):423.
2. Moradi M, Meamar AR, Akhlaghi L, Roozbehani M, Razmjou E. Detection and genetic characterization of *Echinococcus granulosus* mitochondrial DNA in serum and formalin-fixed paraffin embedded cyst tissue samples of cystic echinococcosis patients. *PloS One*. 2019;14(10):e0224501. [DOI:10.1371/journal.pone.0224501] [PMID] [PMCID]
3. Ewnte B. Hydatid cyst of the foot: a case report. *J Med Case Rep*. 2020;14(1):1-4. [PMID] [PMCID] [DOI:10.1186/s13256-019-2337-8]
4. Dybicz M, Borkowski PK, Jonas M, Wasiak D, Małkowski P. First Report of *Echinococcus ortleppi* in Human Cases of Cystic Echinococcosis in Poland. *Biomed Res Int*. 2019;2019:2474839. [DOI:10.1155/2019/2474839] [PMID] [PMCID]
5. Mahmoudi S, Mamishi S, Banar M, Pourakbari B, Keshavarz H. Epidemiology of echinococcosis in Iran: a systematic review and meta-analysis. *BMC Infect Dis*. 2019;19(1):929. [PMID] [PMCID] [DOI:10.1186/s12879-019-4458-5]
6. Mirahmadi H, Behravan M, Raz A, Tasa D, Namaei MH, Solgi R. Genotyping of the *Echinococcus granulosus* in Paraffin-Embedded Human Tissue Samples from Iran. *Acta Parasitol*. 2021;66(2):535-42. [DOI:10.1007/s11686-020-00309-9] [PMID]
7. Zhao Q, Luo J, Zhang Q, Leng T, Yang L. Laparoscopic surgery for primary ovarian and retroperitoneal hydatid disease: a case report. *Medicine*. 2018;97(3). [PMID] [PMCID] [DOI:10.1097/MD.0000000000009667]
8. Richards JS, Pangas SA. The ovary: basic biology and clinical implications. *J Clin Investig*. 2010;120(4):963-72. [DOI:10.1172/JCI41350] [PMID] [PMCID]
9. Zare-Bidaki M, Sadrinia S, Erfani S, Afkar E, Ghanbarzade N. Antimicrobial properties of amniotic and chorionic membranes: a comparative study of two human fetal sacs. *J Reprod Infertil*. 2017;18(2):218.
10. Gamoudi A, Ben KR, Farhat K, Khattech R, Hechiche M, Rahal K. Ovarian hydatid cyst. 7 cases. *J Gynecol Obstet Biol Reprod*. 1995;24(2):144-8.

11. Gaym A, Abebe D, Degefe D. Hydatid cyst an unusual cause of ovarian enlargement. *Ethiop Med J.* 2002;40(3):283-91.
12. Adewunmi OA, Basilingappa HM. Primary ovarian hydatid disease in the Kingdom of Saudi Arabia. *Saudi Med J.* 2004;25(11):1697-700.
13. Konar K, Ghosh S, Konar S, Bhattacharya S, Sarkar S. Bilateral ovarian hydatid disease--an unusual case. *Indian J Pathol Microbiol.* 2001;44(4):495-6.
14. Nosrati A, Soleymani E, Davoodi L. Ovarian cancer or hydatidosis? A case report. *Iran J Parasitol.* 2018;13(3):500.
15. Geramizadeh B. Unusual locations of the hydatid cyst: a review from Iran. *Iran J Med Sci.* 2013;38(1):2.
16. Bozkurt M, Bozkurt DK, Cil AS, Karaman M. Primary ovarian and pararectal hydatid cysts mimicking pelvic endometriosis. *Acta Medica Iranica.* 2012;50(12):839-42.
17. Nazari Z, Torabizadeh J. Primary hydatid cyst of the fallopian tube: A case report. *Casp J Intern Med.* 2014;5(3):179.
18. Namavar Jahromi B, Talei AR, Tabei SZ. Primary Hydatidosis of Uterus and Left Fallopian Tube. *Iran J Med Sci.* 2007;32(2):118-20.
19. Hiller N, Zagal I, Hadas-Halpern I. Echinococcal ovarian cyst. A case report. *Int J Reprod Med.* 2000;45(3):224-6.
20. Ganjeifar B, Ghafouri M, Shokri A, Yazdi FR, Hashemi SA. Giant Cerebral Hydatid Cyst: A Rare Case Report. *Clin Case Rep.* 2021;9(3):1774. [\[DOI:10.1002/ccr3.3908\]](https://doi.org/10.1002/ccr3.3908) [\[PMID\]](#) [\[PMCID\]](#)

How to Cite This Article:

Ghanbarzadeh, N., Nadjfai-Semnani, A., Mohammad Nadjafi-Semnani, M., Behravan, M., Zare-Bidaki, M. A Rare Case of Primary Tubo-Ovarian Hydatid Cyst, Approved Pathologically and Molecularly. *J Obstet Gynecol Cancer Res.* 2023; 8(2):184-7.

Download citation:

[BibTeX](#) | [RIS](#) | [EndNote](#) | [Medlars](#) | [ProCite](#) | [Reference Manager](#) | [RefWorks](#)