

Expectant Management Challenge in Cesarean Scar Pregnancy: A Case Report

Somayeh Khanjani¹, Shamin Ghobadi¹, Farahnaz Mardanian², Leila Mousavi Seresht^{1*} 

1. Department of Obstetrics and Gynecology, School of Medicine, Isfahan University of Medical Sciences, Isfahan, Iran
2. Department of Infertility, School of Medicine, Isfahan University of Medical Sciences, Isfahan, Iran



Article Info

 [10.30699/jogcr.8.6.632](https://doi.org/10.30699/jogcr.8.6.632)

Received: 2022/03/19;

Accepted: 2022/06/07;

Published Online: 11 Nov 2023;

Use your device to scan and read the article online



Corresponding Information:

Leila Mousavi Seresht,

Department of Obstetrics and Gynecology,
School of Medicine, Isfahan University of
Medical Sciences, Isfahan, Iran

Email: Lmousavi.lm@gmail.com

ABSTRACT

Cesarean scars in pregnancy have become a worrisome obstetric problem. Furthermore, given the challenge of diagnosis in cases of low suspicion in the initial prenatal sonographic screening, there is still debate over the standard of management. According to rare reported cases, the most acceptable recommendation is still termination of pregnancy to decrease the chance of further maternal dreadful complications. A case of twin pregnancy had been terminated at gestational age of 34 weeks with a history of diagnosis of cesarean scar pregnancy. Since pregnancy at the site of a previous cesarean section is very rare, but due to the complications of this type of pregnancy, choosing a suitable clinical approach for these patients is desirable. This type of pregnancy can increase the value of antenatal care if it can be continued until the fetus is viable and its complications, including placenta accreta and bleeding, are managed.

Keywords: Ectopic pregnancy, Scar, Antenatal care, Twins



Copyright © 2023, This is an original open-access article distributed under the terms of the Creative Commons Attribution-noncommercial 4.0 International License which permits copy and redistribution of the material just in noncommercial usages with proper citation.

Introduction

Due to the progress of health care systems in the field of caring for pregnant mothers, today we are witnessing an increase in cases of ectopic pregnancies (1). One of the rarest areas reported as an ectopic pregnancy site is a previous cesarean scar site. Complications of Caesarian scar pregnancy (CSP) include heavy bleeding leading to hemorrhagic shock and hysterectomy (2).

The management of these patients will be very different; and in different centers, specialists have made recommendations to patients from the decision to terminate the pregnancy to continuing the pregnancy until the time of delivery. In cases of severe abdominal pain or abnormal bleeding, it is recommended to terminate the pregnancy (3). One of the ominous complications of this type of ectopic pregnancy is the presence of abnormality in the placenta, which can lead to the formation of placenta accreta, which is strongly emphasized by those who agree with termination of pregnancy (4).

In 2014, Timor-Tritsch et al. investigated the history of 10 cases of early-diagnosed CSP who decided to continue their pregnancy even with the high pressure of medical consultants on the probable but remarkable poor pregnancy outcomes. They found that the cases reached the age of viability, but had significant complications in terms of adherent placenta accreta. This data was confirmed by Tamada et al., too (5).

Case Presentation

A 34-year-old G3L2 female with a history of two previous cesarean sections and overt diabetes mellitus was referred with the diagnosis of a twin pregnancy accompanied by abnormal placentation. The ultrasound revealed two gestational sacs at a gestational age of 7 weeks and one day, with a diagnosis of dichorionic diamniotic pregnancy. One of the placentas was placed completely in the anterior lower uterine segment in the previous cesarean section scar, with no obvious invasion to the bladder, but only a myometrium thickness of 3.5mm. Despite several

sessions of discussion with maternal-fetal medicine specialists and obstetricians to illustrate the preferred treatment and risk of expectant management, the parents insisted on a strong desire to preserve these fetuses with the risk of hysterectomy and even fatal bleeding. The parents gave consent and participated regularly in close follow-up with bimonthly ultrasounds in a tertiary center. She experienced no complications up to the gestational age of 24 weeks, when, for the first time, an ultrasound examination showed suspected evidence of focal placenta accreta. The cervical length at 18 and 33 weeks was 35mm and 29mm, respectively. Surprisingly, with the help of close monitoring, this twin pregnancy proceeded to the gestational age of 34 weeks uneventfully when she was

admitted with the plan of 2 doses of antenatal corticosteroids administration and elective section considering the expected lung maturity (Figure.1). During the procedure of cesarean section, no one could believe the identification of uterine dehiscence of the previous uterine scar with no admitted symptoms; anterior placenta previa was also present (Figure.2). The classic incision was done, and two live fetuses were delivered in cephalic and breech positions after pushing down the lone overlying uterovesical peritoneal folds. Both fetuses were healthy, with no need for cardiopulmonary resuscitation. During the surgery, two units of packed cells were transfused. The patient was also followed with a normal physical exam and healing of scars in 10 and 30 days after discharge.

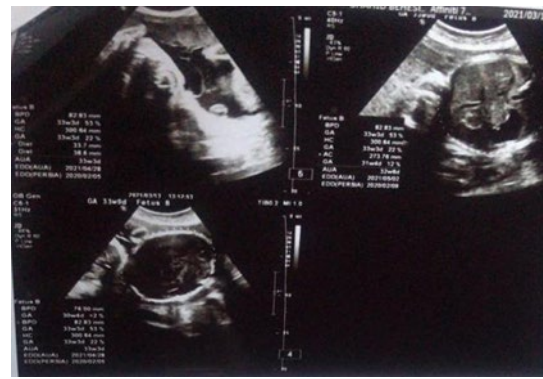
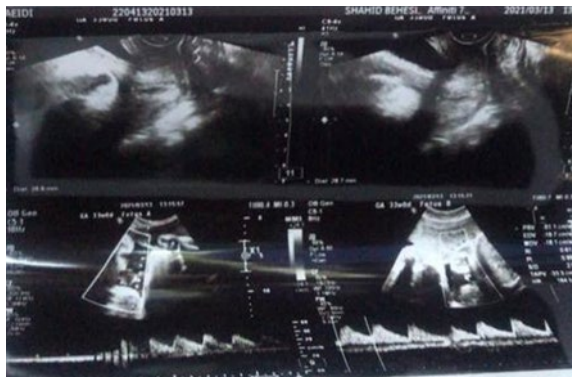
Figure 1. Ultrasound examination showed twin pregnancy with suspected evidence of focal placenta accreta.

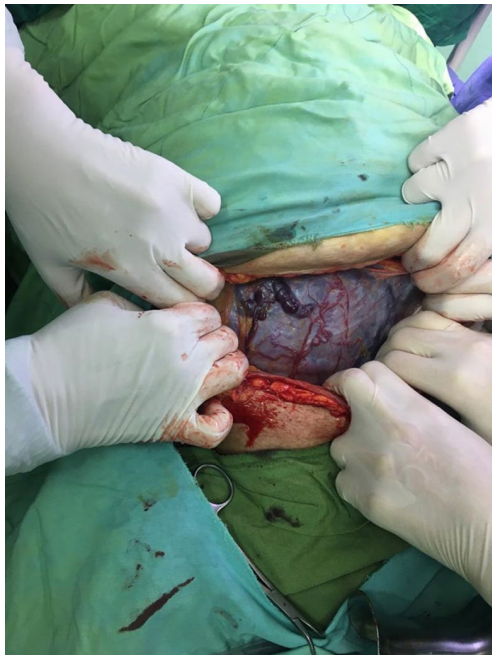


Figure 2. Evidence of uterine dehiscence and placenta previa at the time of cesarean section.

Discussion

Because CSP is reported to be about one in 2,000 pregnancies, it is important to have enough knowledge about the best clinical approaches because it would not

be so rare in females with a history of at least one cesarean section experience, in which the chance level is up to 0.15% and even more in the case of transferring in vitro fertilization (5). However, since the first case of CSP was reported in 1978, in practice there is limited evidence about the exact risk factors of CSP, as a potential life-threatening pregnancy (6). It seems that not only the time interval, number or indication of previous cesarean sections, but also other types of uterine surgery like myomectomy, hysteroscopy, or dilation and curettage, or even manual removal of the placenta could possibly cause such a defect for abnormal implantation of the gestational sac (7).

For a long time, it was assumed that neglecting this diagnosis in early pregnancy could lead to uterine rupture, intraperitoneal hemorrhage, and even death, or at least permanent loss of fertility by hysterectomy with the cost of waiting for fetus maturity. On the other hand, it seems that early identification and management at a gestational age of 12 weeks is more achievable, especially with 5-12 MHZ probes and signs of increased blood flow with a peak systolic velocity of more than 20cm / s and a pulsatility index of less than 1 in Doppler (8, 9). As there is no argument on the necessity of pregnancy termination in CSP cases, there is an inconclusive recommendation on the first-line therapy via hysteroscopic evacuation of gestational product in combination with local or systemic methotrexate or other cytotoxic agents and even uterine

artery embolization or wedge resection by laparoscopy in the next step, based on ultra-sonographic findings, HCG levels, and the surgeon's experiences. But this is not the end, there is no confidential evidence on the safety and success of later pregnancies in such cases (3).

In support of our hypothesis on the possibility of giving the chance of expectant management to pregnant patients with CSP, is the Gonzalez et al. theory in 2017 on two types of CSP, one with an aggressive nature, or exogenic type, and the other with a silent feature and no harm, or endogenic type (10). There is also a reviewing nature study on 24 cases by Haiyan Yu et al., who confirmed the possibility of expectant management in cases of twin pregnancy with one embedded placenta in a cesarean scar, or in other words, heterotopic CSP, with early pregnancy termination of the fetus with abnormal placentation and continuation of pregnancy with the other (11). But the significant difference between that study and the present report, despite the spontaneous occurrence of twin pregnancy in the present case without history of assisted reproductive technology, is success in giving the opportunity of viability to both fetuses with vigilant monitoring of ultrasonography and patient symptoms in a tertiary center, like only one other reported case by Kim in 2014 (Successful full-term twin deliveries in heterotopic cesarean scar pregnancy in a spontaneous cycle with expectant management, 2014). There is no inconclusive guideline in the case of twin pregnancy with HCSP, the achievable recommendations are

selective fetal reduction under the guidance of ultrasonography, with the remaining risk of cytotoxic agent on the rescued intrauterine fetus or even a poor obstetric outcome (3).

The patient's characteristics that led to the report included the presence of concomitant twin pregnancies, continued pregnancy despite the presence of placenta accreta, and the delivery of two live and healthy neonates.

Conclusion

Since pregnancy at the site of a previous cesarean section is very rare due to the complications of this type of pregnancy, choosing a suitable clinical approach for these patients is desirable.

This type of pregnancy can increase the value of antenatal care if it can be continued until the fetus is viable and its complications, including placenta accreta and bleeding, are managed.

Acknowledgments

We would like to thank the admirable efforts of health care providers in the horror situation of the recent COVID-19 pandemic and pray for them.

Conflict of Interest

None.

References

1. Timor-Tritsch IE, Monteagudo A. Unforeseen consequences of the increasing rate of cesarean deliveries: early placenta accreta and cesarean scar pregnancy. A review. *Am J Obstet Gynecol.* 2012; 207(1):14-29. [DOI:10.1016/j.ajog.2012.03.007] [PMID]
2. Timor-Tritsch IE, Monteagudo A, Santos R, Tsymbal T, Pineda G, Arslan AA. The diagnosis, treatment, and follow-up of cesarean scar pregnancy. *Am J Obstet Gynecol.* 2012;207(1): 44.e1-13. [DOI:10.1016/j.ajog.2012.04.018] [PMID]
3. Birch Petersen K, Hoffmann E, Rifbjerg Larsen C, Nielsen HS. Cesarean scar pregnancy: a systematic review of treatment studies. *Fertil Steril.* 2016;105(4):958-67. [DOI:10.1016/j.fertnstert.2015.12.130] [PMID]
4. Timor-Tritsch IE, Monteagudo A, Cali G, Vintzileos A, Viscarello R, Al-Khan A, et al. Cesarean scar pregnancy is a precursor of morbidly adherent placenta. *Ultrasound Obstet Gynecol.* 2014;44(3):346-53. [DOI:10.1002/uog.13426] [PMID]
5. Tamada S, Masuyama H, Maki J, Eguchi T, Mitsui T, Eto E, et al. Successful pregnancy located in a uterine cesarean scar: A case report. *Case Rep Women's Health.* 2017;14:8-10. [PMID] [PMCID] [DOI:10.1016/j.erwh.2017.03.003]
6. Zosmer N, Fuller J, Shaikh H, Johns J, Ross JA. Natural history of early first-trimester pregnancies implanted in Cesarean scars. *Ultrasound Obstet Gynecol.* 2015;46(3):367-75. [DOI:10.1002/uog.14775] [PMID]
7. Jungkman O, Anderson J. Importance of early detection of cesarean scar ectopic pregnancy. *J Diagn Med Sonogr.* 2015;31(5):318-21. [DOI:10.1177/8756479315597707]
8. Pędraszewski P, Właźlak E, Panek W, Surkont G. Cesarean scar pregnancy - a new challenge for obstetricians. *J Ultrason.* 2018;18(72):56-62. [DOI:10.15557/JoU.2018.0009] [PMID][PMCID]
9. Amoozegar H, Rahmati N, Naseri Z, Shah-Hamzehi s, vahedian m, Noori e, et al. The Role of lower uterine segment thickness to Prediction of Cesarean Scar Defects: two-dimensional

- transvaginal ultrasound Vs. Intraoperative Findings. *J Obstet Gynecol Cancer Res.* 2023.
10. Gonzalez N, Tulandi T. Cesarean Scar Pregnancy: A Systematic Review. *J Minim Invasive Gynecol.* 2017;24(5):731-8. [[DOI:10.1016/j.jmig.2017.02.020](https://doi.org/10.1016/j.jmig.2017.02.020)] [[PMID](#)]
11. Yu H, Luo H, Zhao F, Liu X, Wang X. Successful selective reduction of a heterotopic cesarean scar pregnancy in the second trimester: a case report and review of the literature. *BMC Pregnancy Childbirth.* 2016;16(1):1-7. [[PMID](#)] [[PMCID](#)] [[DOI:10.1186/s12884-016-1171-x](https://doi.org/10.1186/s12884-016-1171-x)]

How to Cite This Article:

Khanjani, S., Ghobadi, S., Mardanian, F., Mousavi Seresht, L. Expectant Management Challenge in Cesarean Scar Pregnancy: A Case Report. *J Obstet Gynecol Cancer Res.* 2023;8(6):632-5.

Download citation:

[RIS](#) | [EndNote](#) | [Mendeley](#) | [BibTeX](#) |