

# Primary Bilateral Fallopian Tube Carcinoma: A Rarity

Isha Nandal\*, Roopa Malik, Krishna Dahiya

Department of Obstetrics and Gynaecology, PGIMS, Rohtak, Haryana, India



## Article Info

doi [10.30699/jogcr.8.6.636](https://doi.org/10.30699/jogcr.8.6.636)

Received: 2022/08/06;

Accepted: 2022/12/24;

Published Online: 11 Nov 2023;

Use your device to scan and read the article online



## Corresponding Information:

Isha Nandal,

Department of Obstetrics and Gynaecology,  
PGIMS, Rohtak, Haryana, India

Email: [ishadahiya2018@gmail.com](mailto:ishadahiya2018@gmail.com)



Copyright © 2023, This is an original open-access article distributed under the terms of the Creative Commons Attribution-noncommercial 4.0 International License which permits copy and redistribution of the material just in noncommercial usages with proper citation.

## ABSTRACT

Primary fallopian tube carcinoma is a very rare gynecological malignancy and poses a challenge in diagnosis preoperatively. We are reporting a rare case of bilateral primary fallopian tube carcinoma in a 48-year-old lady with classical symptoms. These symptoms are seen in less than 15% of cases. The differential diagnosis for bilateral fallopian tube cancer includes secondary malignancies arising from endometrial, ovarian and gastrointestinal cancers. Although the prognosis is poor. Early diagnosis, optimum cytoreduction and adjuvant chemotherapy are important to improve survival in such patients.

**Keywords:** Fallopian Tube Carcinoma, Gynecological Malignancy, Bilateral Primary Carcinoma, Secondary Malignancies

## Introduction

Primary fallopian tube carcinoma (PFTC) is rare, accounting for 0.14-1.8% of total gynecological cancers and histologically resembling epithelial ovarian cancers (1). The reporting of bilateral fallopian tube cancers accounts for only 20% of all PFTC (2). PFTC most commonly occurs between the 4th and 5th decades of life, and has a short history of symptoms. It is sometimes associated with an inherited BRCA mutation. The classical triad of PFTC patients consists of pelvic pain, abdominal mass and episodes of watery vaginal discharge. However, this triad is seen in only 1/8th of the presenting patients. The differential diagnosis for bilateral fallopian tube cancer includes secondary malignancies arising from endometrial, ovarian and gastrointestinal cancer (3). This case is being reported as a rare incidence.

## Case Presentation

We present the case of a 48-year-old P3L3 premenopausal patient with complaints of abdominal distension along with mild pain in the abdomen and vaginal discharge for the last 4 months.

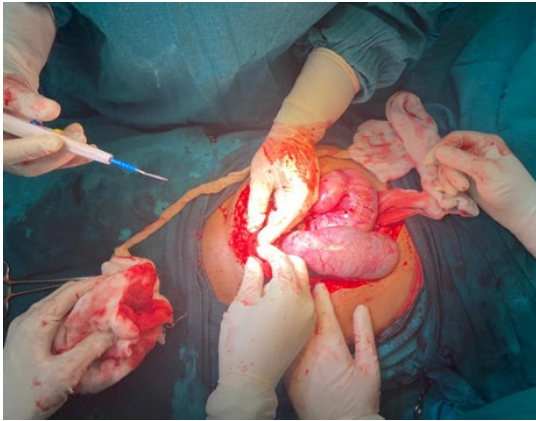
On abdominal examination, ascites was present along with a firm, tender, mobile mass of size around 12\*7 cm felt in the right iliac fossa and another mass of 7\*6 cm felt in the left iliac fossa. Serous discharge was present on speculum examination. On bimanual examination, the uterus was anteverted, normal size, along with a firm, mobile, tender mass of 12\*8 cm felt through the right fornix and another firm, mobile, tender mass of 10\*7 cm felt through the left fornix.

Liquid-based cytology showed normal cytology. CA-125 was 1966.30 U/ml. CECT was done, which showed a heterogenous enhancing lesion in the abdominopelvic region abutting the uterus seen on the right adnexa of approximately 148\*86\*170 mm and in the left adnexa of 116\*62\*104 mm size with bilateral ovaries not seen separately.

In view of the presence of the classical triad of a watery discharge, a pelvic mass and pelvic pain, a diagnosis of fallopian tube carcinoma was suspected. Although the CT scan was suggestive of ovarian malignancy.

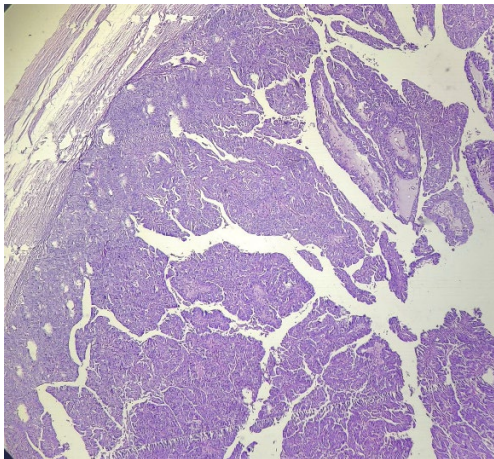
The patient was taken up for staging laparotomy and proceeded with a provisional diagnosis of ovarian carcinoma, which was intraoperatively confirmed as a

bilateral fallopian tube tumor ([Figure 1](#) and [Figure 2](#)). A bilateral tubal mass was found during the operation,

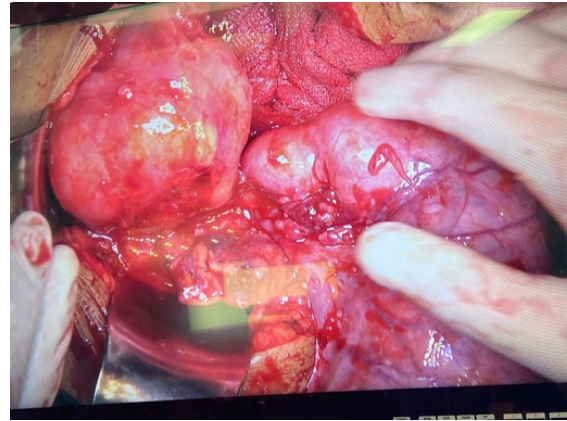


**Figure 1.** Showing bilateral fallopian tubes tumor during the surgery

The patient underwent TAH-BSO (Total abdominal hysterectomy and bilateral salpingo-oophorectomy) with total omentectomy and selective lymphadenectomy. Histopathological examination showed bilateral tubal high-grade papillary



and the ovaries were separate from the mass. Ascites was noted, along with no peritoneal deposits.



**Figure 2.** Showing uterus with left fallopian tube tumor

adenocarcinoma with lymphovascular and parametrium involvement ([Figure 3](#)). She was scheduled for six cycles of adjuvant chemotherapy with carboplatin and paclitaxel. There was no evidence of recurrence on a regular follow-up of 1 year.

**Figure 3.** H&E staining suggestive of growth arising from the fallopian tube wall and presence of papillary projections in the malignant growth

## Discussion

Diagnosing PFTC is challenging as it resembles epithelial ovarian cancer clinically and histologically (4). PFTC is usually seen earlier than epithelial ovarian cancer as a result of abdominal pain from tubal distension and a shorter history of symptoms in PFTC (5). The causes of PFTC are unknown. Pregnancy and the use of OCPs (Oral contraceptive pills) decrease the risk of PFTC (6). High parity is also seen as protective from PFTC. PFTC is mostly seen in postmenopausal patients. The mean age of incidence is 55 years, and peak incidence ranges between 60-64 years (7).

Our patient was premenopausal, and predisposing factors like nulliparity, PID (Pelvic inflammatory disease), and subfertility were not seen. Latzko's triad includes intermittent colicky pain relieved by

discharge, profuse serosanguineous vaginal bleeding, and an abdominal or pelvic mass. Only 15% of PFTC cases present with Latzko's triad (8). However, all of these symptoms were present in our case.

PFTC is extremely difficult to diagnose preoperatively with a reported diagnosis range of 0-10%, and up to 50% are missed intraoperatively as well (9-11). Pap smears were negative for our patient. However, the CA-125 level, which acts as a useful tumor marker for the diagnosis, was elevated in our case. Most PFTC patients present with raised pretreatment CA-125 levels (12). Imaging modalities for suspected gynecologic malignancies include USG, CT and MRI. For detecting tumor infiltration of extramural organs, MRI is considered better than CT.

The diagnostic criteria for PFTC are: the primary tumor is from the tube and originates from mesosalpinx, the histological pattern reproduces the tubal mucosa epithelium with a clear and demonstrable transition from benign to malignant; and the ovaries and endometrium are normal. In our case, all four criteria were fulfilled. Retroperitoneal and distant metastasis rates are higher in PFTC. Staging laparotomy is the treatment of choice. The procedure of choice for any stage of fallopian tube carcinoma is TAH-BSO, omentectomy, selective pelvic and para-aortic lymphadenectomy (13, 14).

Similar to epithelial ovarian cancer, the most commonly used postoperative therapy for PFTC patients is platinum-based combination adjuvant chemotherapy. Also, no consensus exists on the role of postoperative radiotherapy (13, 15). Prognostic factors for PFTC are staging, ascites, histologic grade and residual volume of the tumor after cytoreduction (13, 16). Ashraf Ganjoei and others reported serous borderline tumor of the fallopian tube in a 32 year old female with 68×74 mm persistent right adnexal cyst

(17). Our case had typical clinical features, though the imaging modalities suspected ovarian malignancy, but a definitive diagnosis was made postoperatively.

## Conclusion

PFTCs are rare gynecological tumors that are very difficult to diagnose preoperatively. Early-stage laparotomies and primary cytoreduction surgery remain the keys to prolonging the survival of PFTC patients. For better treatment, paclitaxel and carboplatin or single-agent carboplatin chemotherapy is a valid option.

## Acknowledgments

None.

## Conflict of Interest

None.

## References

- Kalampokas E, Kalampokas T, Tourountous I. Primary fallopian tube carcinoma. *Eur J Obstet Gynecol Reprod Biol.* 2013;169(2):155-61. [DOI:10.1016/j.ejogrb.2013.03.023] [PMID]
- Markman M, Zaino R, Fleming P, et al. Carcinoma of the fallopian tube. *Principles and Practice of Gynecologic Oncology: Lippincott Williams and Wilkins; 2000.* p. 1099 -112.
- Honoré L. Pathology of the fallopian tube and broad ligament. *Haines and Taylor Obstetrical and Gynecologic Pathology.* New York: Churchill Livingstone; 2003. p. 605-15.
- Tahiri Elousrouti L, Erragad FZ, Jayi S, Hammas N, Harmouch T, Chbani L, et al. Primary adenocarcinoma of the fallopian tube: Report of two cases. *J Clin Case Rep.* 2016;6(5):1000792. [DOI:10.4172/2165-7920.1000792]
- Moore KN, Moxley KM, Fader AN, Axtell AE, Rocconi RP, Abaid LN, et al. Serous fallopian tube carcinoma: A retrospective, multi-institutional case-control comparison to serous adenocarcinoma of the ovary. *Gynecol Oncol.* 2007;107(3):398-403. [DOI:10.1016/j.ygyno.2007.09.027] [PMID]
- Riska A, Leminen A. Determinants of incidence of primary fallopian tube carcinoma (PFTC). *Cancer Epidemiol.* 2009;387-96. [DOI:10.1007/978-1-60327-492-0\_18] [PMID]
- Jeung IC, Lee YS, Lee HN, Park EK. Primary carcinoma of the fallopian tube: report of two cases with literature review. *Cancer Res Treat.* 2009;41(2):113-6. [PMID] [PMCID] [DOI:10.4143/crt.2009.41.2.113]
- Lau H-Y, Chen Y-J, Yen M-S, Chen R-F, Yeh S-O, Twu N-F. Primary fallopian tube carcinoma: A clinicopathologic analysis and literature review. *J Chin Med Assoc.* 2013;76(10):583-7. [DOI:10.1016/j.jcma.2013.06.010] [PMID]
- Koo Y-J, Im K-S, Kwon Y-S, Lee I-H, Kim T-J, Lim K-T, et al. Primary fallopian tube carcinoma: a clinicopathological analysis of a rare entity. *Int J Clin Oncol.* 2011;16:45-9. [DOI:10.1007/s10147-010-0128-8] [PMID]
- Huber-Buchholz M-M, Buchholz N-P, Staehelin J. Analysis of 23 Cases of Primary Carcinoma of the Fallopian Tube over 50 Years. *J Obstet Gynaecol Res.* 1996;22(3):193-9. [PMID] [DOI:10.1111/j.1447-0756.1996.tb00966.x]
- Horng H-C, Teng S-W, Huang B-S, Sun H-D, Yen M-S, Wang P-H, et al. Primary fallopian tube cancer: Domestic data and up-to-date review. *Taiwan J Obstet Gynecol.* 2014;53(3):287-92. [DOI:10.1016/j.tjog.2014.07.003] [PMID]
- Chaudhry S, Hussain R, Zuberi MM, Zaidi Z. Rare primary fallopian tube carcinoma; a gynaecologist's dilemma. *J Pak Med Assoc.* 2016;66(1):107-10.
- Berek JS, Crum C, Friedlander M. Cancer of the ovary, fallopian tube, and peritoneum. *Int J Gynaecol Obstet.* 2015;131(S2):S111-S22. [DOI:10.1016/j.ijgo.2015.06.007] [PMID]

14. Veloso Gomes F, Dias JL, Lucas R, Cunha TM. Primary fallopian tube carcinoma: review of MR imaging findings. *Insights Imaging*. 2015;6(4):431-9. [[DOI:10.1007/s13244-015-0416-y](https://doi.org/10.1007/s13244-015-0416-y)] [[PMID](#)] [[PMCID](#)]
15. Pectasides D, Pectasides E, Economopoulos T. Fallopian tube carcinoma: a review. *Oncologist*. 2006;11(8):902-12. [[DOI:10.1634/theoncologist.11-8-902](https://doi.org/10.1634/theoncologist.11-8-902)] [[PMID](#)]
16. Hariprasad P, S H, Srinivas T, Shetty KJ. Primary bilateral fallopian tube carcinoma the report of a single case with review of the literature. *J Clin Diagn Res*. 2013;7(5):930-2. [[PMID](#)] [[PMCID](#)] [[DOI:10.7860/JCDR/2013/5483.2980](https://doi.org/10.7860/JCDR/2013/5483.2980)]
17. Ashraf Ganjoei T, Talayeh M, Afsharmoghadam N, Norouzi AR, Noei Teymoordash S. Serous Borderline Tumor of the Fallopian Tube: A Case Report and Literature Review. *J Obstet Gynecol Cancer Res*. 2022;7(6):583-6. [[DOI:10.30699/jogcr.7.6.583](https://doi.org/10.30699/jogcr.7.6.583)]

#### How to Cite This Article:

Nandal, I., Malik, R., Dahiya, K. Primary Bilateral Fallopian Tube Carcinoma: A Rarity. *J Obstet Gynecol Cancer Res*. 2023;8(6):636-9.

**Download citation:**

[RIS](#) | [EndNote](#) | [Mendeley](#) | [BibTeX](#) |