

# Assessment of Cesarean Scar Following Conservative Management for Placenta Accreta Spectrum at a Tertiary Care Hospital in Egypt

Mona K. Omar<sup>1</sup> , Ayman S. Dawood<sup>1\*</sup> , Samah Ahmed Radwan<sup>2</sup> , Ahmed M. Ossman<sup>1</sup> 

1. Department of Obstetrics and Gynecology, Tanta University, Tanta, Egypt
2. Department of Radiodiagnosis, Tanta University, Tanta, Egypt



## Article Info

 [10.30699/jogcr.9.2.167](https://doi.org/10.30699/jogcr.9.2.167)

**Received:** 2023/05/19;

**Accepted:** 2023/08/16;

**Published Online:** 13 Mar 2024;

Use your device to scan and read the article online



## Corresponding Information:

**Ayman S. Dawood,**  
Department of Obstetrics and Gynecology,  
Tanta University, Tanta, Egypt

**Email:** [ayman.dawood@med.tanta.edu.eg](mailto:ayman.dawood@med.tanta.edu.eg)

## ABSTRACT

**Background & Objective:** Conservative treatment of placenta accreta spectrum (PAS) become increasingly performed, especially due to acceptance of many obstetricians to preserve the uterus. To evaluate cesarean scar integrity following PAS conservative surgery using Shehata's technique and other conservative techniques because more than one level of pelvic devascularization was used. This cross-sectional study was conducted at Tanta University in the period from June 1, 2019 to October 31, 2022.

**Materials & Methods:** All patients underwent conservative uterine sparing technique (Shehata's technique) were assessed by 2 D ultrasound at 6-18 months later to detect the integrity of the CS scar. Fifty women with a history of other conservative treatment of PAS used as control.

**Results:** Women who were operated with Shehata's technique showed less incidence of scar dehiscence with less size of scar defects and more thickness of the myometrium over the scar site and more vascularity of these scars.

**Conclusion:** Shehata's technique resulted in a more integrated scar with less incidence of dehiscence and more vascularity of the compared to other conservative methods of treatment of PAS. Therefore, it is an effective and safe method in treatment of PAS.

**Keywords:** Conservative Treatment, Placenta Accreta Spectrum, Uterine Sparing, Placenta Accreta, Scar Assessment, Ultrasound



Copyright © 2024, This is an original open-access article distributed under the terms of the Creative Commons Attribution-noncommercial 4.0 International License which permits copy and redistribution of the material just in noncommercial usages with proper citation.

## Introduction

Placenta accreta spectrum (PAS) is a group of disorders that describe partial or complete adhesion of the placenta to the myometrium. The rate varies dramatically since the 2000 to be 1 per 2500 deliveries varying from one country to another according to clinical environment, increased safety of the procedure, patient request and fear of litigations (1). Pregnancy in a scarred uterus increased the incidence of placenta accreta spectrum. Placenta accreta spectrum causes significant maternal morbidity and mortality (2).

Most of the multicenter studies have demonstrated the importance of conservative treatment in PAS due to high success in preservation of the uterus (78.4%) of women and avoided hysterectomy, thereby maintaining future fertility. There was only 6% rate of severe maternal morbidity (3).

The three-step (Shehata's) technique, is one of the new treatment options for the PAS. This technique had very good advantage in preservation of the uterus without more increase in the incidence of the blood

loos. This procedure includes three main steps; the first one is ligation of both uterine arteries before placental separation at isthmus and above uterine incision, the second step is application of quadrant suture to control bleeding from lower uterine segment (LUS) after placenta separation and the third step is insertion of triple way folly's catheter for compression and drainage (4).

Assessment of cesarean scars by ultrasound had the advantage of being non-invasive if compared to hysteroscopy or hysterosalpingography. Ultrasound assesses diameter and the morphology of cesarean scars and the integrity of LUS.

In this study, we tried to follow up the long-term impact of this conservative management for placenta accreta on scar integrity. We also described scar characteristics accurately as well as the appearances of LUS to diagnose the long-term outcomes of this procedure.

## Methods

### Study design and setting

This cross-section, single center study was conducted at Tanta University, Tanta, Egypt in the period from June 1, 2019, to October 31, 2022. This study was conducted on an outpatient basis. Data Privacy and security measures were maintained throughout the study.

### Inclusion criteria

We included in this study all women with placenta accrete spectrum that were operated with uterine sparing techniques with an interval from last cesarean was between 6-18 months postoperative. The exclusion criteria were women with a history of placenta accrete spectrum operated with hysterectomy and inability to see the scar.

### Allocation

Group 1 (study group): included 97 women who were managed by Shehata's technique and group 2 (control group) included 50 women who were managed by other conservative techniques.

### Methods

Participants were examined 6-18 months postoperative using transabdominal and transvaginal ultrasound. All the examinations were done by the same operator using the Mindray DC-70 machine with frequency of 3.5–5-MHz and 6-MHz for abdominal and transvaginal transducers respectively. Doppler's velocimetry of cesarean scars was done for all the patients.

Demographic data and detailed history of the last delivery were collected, including number of previous cesarean deliveries, postoperative complications and interval since the last delivery. The optimal time for CS scar assessment was proposed at six-month interval to allow for better healing of uterine scar and recommended not to scan earlier due to scar deformity from wound edema (5, 6).

In our study, we assessed uterine scar and the remaining myometrium above the scar. Cervico-isthmic canal (CIC), uterine scar and LUS were assessed in the mid sagittal plane. Depth was modified to acquire a panoramic view of LUS and cervical canal to external os. Clear visualization of the endocervical canal must be obtained without excessive pressure on the cervix to avoid elongation of the cervix. Internal os is located at the lower narrowing of LUS. After identifying the CS scar, zooming was applied to magnify the picture to allow better and accurate measurements.

The scar was defined as a wedge-shaped hypoechoic area in the anterior uterine wall at the cesarean wound site, lying between the internal os and uterovesical fold. The scar should be measured in three dimensions (length, width and depth) in sagittal and

transverse planes. The CS scar was further classified morphologically into type 1 that describes a narrow linear defect, or type 2 that describes dehiscence wide hypoechoic defect. Finally, CS scar location was determined in relation to the CIC (within or above) (7, 8). Furthermore, Color was used to assess vascularity and blood flow within cesarean scar and detect any pathological flow and evaluate healing of scars.

### Statistical methods

SPSS version 18 (IBM, USA) was used for statistical analysis of data. The statistical tests used were mean, standard deviation and percentage. Comparison of means was done by student's t-test and comparison of percentages by chi-square test.

## Results

Patients attending the outpatient unit of Obstetrics and Gynecology department, Tanta University in study duration with history of placenta accrete surgery were 213 cases. The patients fulfilling inclusion criteria (managed by the Shehata technique) were 102 cases. The excluded patients (61) either did not fulfill inclusion criteria or were managed by hysterectomy. Only 50 patients were used as a controlled group who were managed by other conservative techniques. From the 102 cases, the scars were visible on ultrasound scan in 97/102 (95.1%) women. The flow of cases during the study is shown in [Figure 1](#).

Demographic data of enrolled patients are included in [Table 1](#). These characteristics include age, BMI, parity, previous uterine surgery, number of previous CS, postoperative fever, interval since the last CS. There was no significant difference between both groups.

The scars were identified on ultrasound scan in 97 women. The total number of visible scars of defect are 7/97 (7%) in women with a single previous section, 26/97 (26.8%) in women with two previous CS and 64/97 (65.9%) in those with three or more.

[Table 2](#) shows comparisons between both groups as regard to ultrasound appearance of the scar. As for the studied group, the majority of scars were located above the internal os, but 33/97 (34%) women had evidence of scar location at the Inter os. This is almost the same result in the control group 15 (30%) at the internal os, 35(70%) higher scar location (P 0.32). Among the women who had Shehata technique, the median distance between the scar and the internal cervical os was (8.5, 5.8 and 4.08) mm, in women with previous one, two, and three or more CS respectively. There was a significant difference regarding the distance between scar of CS and internal os in cases with prior two CS, and those with  $\geq 3$  CS (P=0.01 and 0.0004) respectively as shown in [Table 3](#).

The incidence of the scar defects was smaller in cases treated with Shehata's technique (74.2% Vs 84% in the control group with no significant difference as shown

in [Table 2](#). Also, the incidence increases with the number of Cesarean sections (42.8, 61.5, 85.9%) respectively as shown in [Table 3](#).

The morphological appearance of CS scars, either type 1 or type 2 was shown in [Figure 2](#). Most cases of Shehata's technique were type 1 (67%) with significant difference between both groups (p 0.0001). In [Table 3](#), the incidence of both types of the scar in the 3 subgroups of Shehata technique with no significant different between them in the linear type of the scar (type 1) but the different was significant between them in the dehiscence type of the scar (type 2) as shown in [Table 2](#).

The cases with scar defect were examined for the size of residual myometrial thickness at the site of CS. Defects were severe in 27/74 women (36%) involving

$\geq 50\%$  of the myometrium versus 15/ 42 (44%) in the control group ([Table 2](#)).

Measuring the thickness of the remaining myometrial can be used as a predictor of uterine scar dehiscence. Our study shows that myometrial thickness of 10-12 mm occurs in a greater number of women (16 /74) that results in more integrated scar and less liability for dehiscence.

By using the Doppler scan, vascularity of the scar was evaluated and the vascularization patterns of cesarean scars are presented in [Figure 3](#). The scar is usually more hypovascularized. In The women with Shehata technique it is relatively more vascular with no significant difference between both groups (P =0.5). These are shown in [Figure 3](#).

**Table 1. Demographic data of enrolled patients (n=147)**

Parameter	Study group (n= 97)		Control group (n=50)		P
Maternal age (mean, range)	32.44 (27–39)		35.33 (30- 39)		P 0.1
BMI (mean, range)	26.8 (20-38)		30.8 (24-39)		P 0.1
Number of previous scar (n, %)					
One	7	(7%)	0	(0%)	P 0.1
Tow	26	(26.8%)	11	(22%)	P 0.1
Three or More	64	(65.9%)	39	(78%)	P 0.1
Postoperative complication (n, %)					
pyrexia	5 (5%)		9(18%)		P 0.1
blood transfusion	23 (24%)		15 (30%)		
interval since the last CS (months)	9.77 (6-18)		10 (6-18)		P 0.1

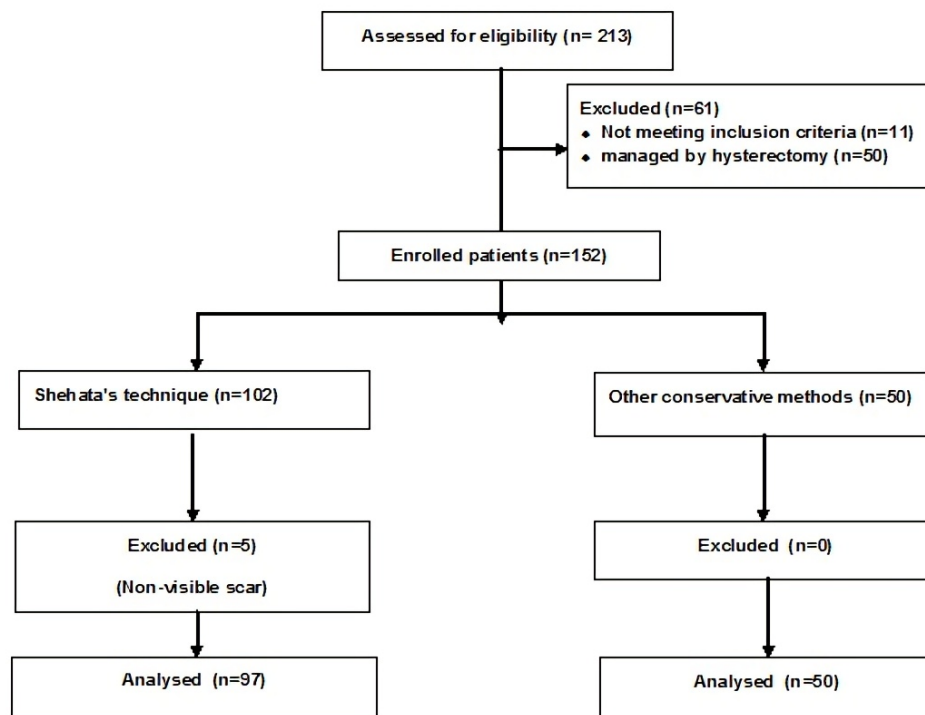
**Table 2. Ultrasound findings in women of both groups**

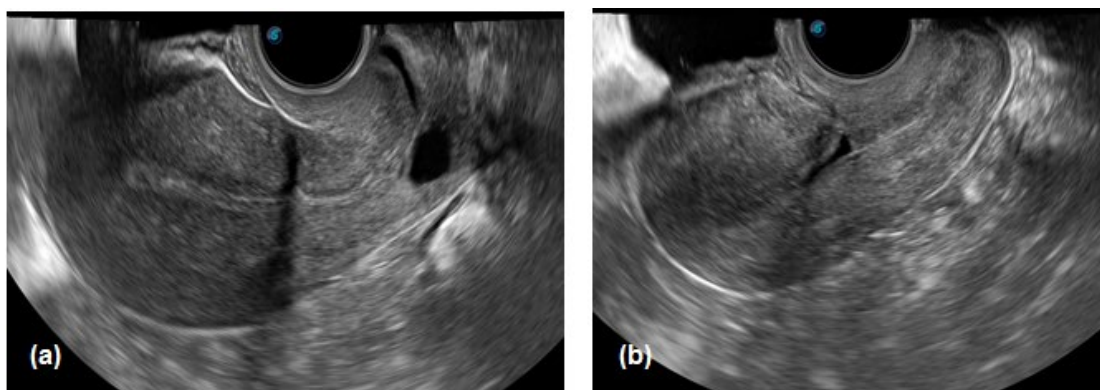
	Study group (n= 97)	Control group (n= 50)	P	
Mean distance between the scar and IO	4.8 (0-15)	5.16 (0-10)	P	0.07
Scar at the internal os (n, %)	33 (34%)	15(30%)	P	0.3
Higher scar location (n, %)	64 (66%)	35 (70%)		
Patients with Scar defect (n, %)	74(76.2%)	42 (84%)	p	0.10
Incidence of linear defect (type 1)	50 (67%)	12 (28%)	p*	0.0001
Incidence of dehiscence (type 2)	24 (33%)	30 (72%)	p*	0.0001
Residual Myometrial thickness at site of the defect (mm)	6.5(1.2-12)	5.08(0.9-12)	p	0.027
Residual myometrial tissue over the defect < 50% (n, %)	27 (36%)	15 (35%)	p	0.4

P1 one cs, two cs - P2 two cs, three or more cs - P3 one cs, three or more cs

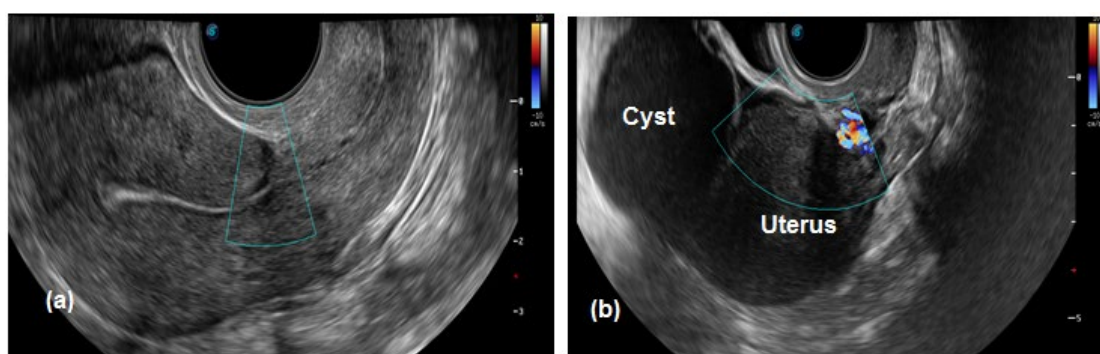
**Table 3.** Ultrasound findings in study group in relation to number of cesarean sections (n=97)

	Studied group (n= 97)	One CS (n=7)	Two CS (n=26)	Three, more cs (n=64)	P	
<b>Mean distance between the scar and IO</b>	4.8 (0-15)	8.5(0-15)	5.8 (0-10)	4.08 (0-9)	P1	0.07
					P2*	0.01
					P3*	0.0004
<b>Patients with Scar defect (n, %)</b>	74 (76.2%)	3 (42.8%)	16 (61.5%)	55 (85.9%)	P1	0.2
					P2*	0.01
					P3	0.03
<b>Incidence of linear defect (type 1)</b>	50 (67%)	3 (100%)	8 (50%)	42 (76%)	P1	0.11
					P2	0.04
					P3	0.3
<b>Incidence of dehiscence (type 2)</b>	24 (33%)	0 (0%)	8 (50%)	13 (24%)	P1*	0.001
					P2*	0.007
					P3*	0.0001
<b>Remaining Myometrial thickness at site of the defect (mm)</b>	6.5(1.2-12)	5.6 (4-7)	4.8 (1.2-10)	3.2 (1.2-8)	P1	0.4
					P2	0.09
					P3*	0.01
<b>Thickness of remining myometrial over the defect &lt; 50%</b>	27 (36%)	1 (33%)	5 (31%)	21 (38%)	P1	0.9
					P2	0.6
					P3	0.8

**Figure 1.** Flow chart of patients throughout the study



**Figure 2.** (a) Cesarean scar niche type 1 (b) Cesarean scar defect type 2



**Figure 3.** (a) Colour Doppler showing hypovascular scar (b) Vascularized cesarean scar

## Discussion

The most important goal of the conservative management is to preserve the uterus for future fertility. Good condition of the uterine scar with no defects, good myometrial thickness over CS scar and good vascularity all reduce the risk of complications in future pregnancies as scar rupture or dehiscence and scar ectopic pregnancy or later on PAS. Good scars also had decreased incidence of niche, intermenstrual bleeding, and subfertility (9).

Our results show the long-term outcome of one of the successful conservative treatments for placenta accreta that is Shehata technique on the uterine scar. The technique shows more integrated scar, with most scars located above the internal os (66%). The incidence of the scar defect was less (74.2% Vs 84%) in the control group but with no significant difference. Also, the incidence increases with more repeat cesarean sections that the women did before the procedure. As regards to the morphological appearances of the scar, most cases of Shehata technique were type 1 (67%) with significant difference between both groups ( $p < 0.0001$ ). Our study shows that the good remaining myometrium thickness occurs in a greater number of women that results in more integrated scar and less liability for dehiscence. In 27/74 women (36%) the defects were severe with  $\geq 50\%$  myometrial involvement compared to 15/42 (44%) in the control group.

As regard to the demographic data of all the including patients at the time of examination, there was no significant different between both groups. As for postoperative pyrexia, need for blood transfusion in the operation control group show more incidence with no significant different between the groups.

We evaluated CS scar 6-18 months after delivery, as an earlier examination of scars yields in false results due to wound edema (6). Dicle, Küçükler (10) used magnetic resonance imaging (MRI) to assess cesarean scar healing. They reported that at least three months to form, and six months for complete involution of tissue edema and restoration of zonal anatomy are needed (10).

As for the scar location, both groups show that most scars were located at a higher location above internal os. In the women who had Shehata's technique, the median distance between the scar and the internal cervical os was (8.5, 5.8 and 4.08 mm) in women with previous one, two, and three or more CS, respectively. There was a significant difference regarding the distance between cases with prior two cs, and those with three or more ( $P=0.01$  and  $0.0004$ ) respectively. Ofili-Yebovi, Ben-Nagi (11) found that if hysterotomy was done close to the internal cervical os and cervical tissue was included in repair, this might affect the healing process and have a negative impact on scar involution and result in larger defects (11). Tulandi and

Cohen (12) found that scar deficiency was increased in proportion to increased number of repeat CS (12).

Roberge et al., in their meta-analysis, described ultrasound definitions and methods that were used in assessment of CS scars. They found great discrepancies in definitions of CS scar defect with different imaging techniques. They used hystero-graphy, Sono hystero-graphy and ultrasound. The detection of cesarean defects was found to be 58% (33 to 70), 59% (58 to 85), and 37% (20 to 65), respectively. They reported that cesarean scar defects were found in nearly 50% of women who delivered by cesarean section (13).

Most of the published studies showed the distribution and difference between small and large scar defects in cases with previous CS. The prevalence of scars with a defect showed great discrepancy in published studies. The range of 56% and 84% was reported by Bij de Vaate, van der Voet (14). Other studies showed an incidence of 37% (13) and 45.6% (15). Discrepancy of results was attributed to many factors, including variability in cesarean delivery indications, operative complications, and differences in ultrasound examination timing in relation to cesarean delivery. Our results agree with others in that the incidence of scar defects is proportionate to increased number of repeat CS (14, 15). This can be explained by repeated trauma to the cesarean wound that disrupts the normal healing process. In our study incidence of the scar defect was insignificantly less in Shehata technique than other conservative methods (74.2% Vs 84%). Also, most cases of Shehata technique were type 1 (67%) with a significant difference between both groups ( $P=0.0001$ ) indicating better healing conditions so better scar in this technique.

In the current study, we found that 36% of women in group 1 had large defects involving  $\geq 50\%$  of the myometrial thickness. Moreover, the percentage increases in cases of multiple sections to 38% in cases with three or more CS. These results may help in detection of women at risk of scar ectopic or scar rupture in subsequent pregnancy. However, scar rupture was reported to be less than 5% with severe defects and scar ectopic was reported approximately one in 1800 pregnancies (16). It was reported that the thinner the scar, the more incidence of scar ectopic pregnancy and proportional to the size of the myometrial defect. On the same side, scar dehiscence and uterine rupture were also increased as the scar is going thinner, although the exact cut-off of this thickness is unknown (17).

Finally, our result shows that scars of Shehata's technique were relatively more vascular, but the

difference was not statistically significant between both groups. This means that Shehata's technique did not affect the vascularity of the uterus so that result in better healing process of CS scars. Other techniques may decrease uterine perfusion, leading to delayed wound healing. Theoretically, conservative treatment might worsen uterine wound healing due to trauma by repeated uterine scars (cesarean), and uterine devascularization procedures. We confirm that Shehata's uterine sparing technique does not appear to affect the vascularity, so it will be of benefit for patients requiring subsequent fertility.

The strength points of this study are the large number of cases included in the study and the presence of a control group. The rate of the placenta accreta is high at Tanta University hospital that we can study the effectiveness of the new conservative management on the large number of cases; especially the conservative treatment for placenta accreta is a rare event in the other centers all over the world. The weakness points are the cross-section design of this study, the absence of follow-up schedule for these patients in the next pregnancy, and we did not study the effects of different contraceptive methods on scar healing and vascularity.

## Conclusion

PAS rate varies dramatically since 2000 depending on the country. The conservative line of treatment becomes a choice to preserve the uterus for future fertility. Shehata's technique is one of the conservative managements of PAS. Our results show the long-term outcome of it on the uterine scar integrity. The technique shows more integrated scars with less incidence of Scar defect, as well as good remaining myometrium thickness occurs in a greater number of women. Our result shows that Shehata's technique did not affect the vascularity of cesarean scar with better healing process.

## Acknowledgments

None.

## Conflict of Interest

The authors declared no conflict of interest.

## Funding

None.

## References

1. El Gelany S, Mosbeh MH, Ibrahim EM, Mohammed M, Khalifa EM, Abdelhakium AK, et al. Placenta Accreta Spectrum (PAS) disorders: incidence, risk factors and outcomes of different management strategies in a tertiary referral hospital in Minia, Egypt: a prospective study. *BMC*

- Pregnancy Childbirth. 2019;19(1):313. [PMCID] [DOI:10.1186/s12884-019-2466-5] [PMID]
2. Morlando M, Collins S. Placenta Accreta Spectrum Disorders: Challenges, Risks, and Management Strategies. *Int J Women's Health*. 2020;12(null):1033-45. [DOI:10.2147/IJWH.S224191] [PMID] [PMCID]
  3. Sentilhes L, Ambroselli C, Kayem G, Provansal M, Fernandez H, Perrotin F, et al. Maternal Outcome After Conservative Treatment of Placenta Accreta. *Obstet Gynecol*. 2010;115(3):526-34. [DOI:10.1097/AOG.0b013e3181d066d4] [PMID]
  4. Dawood AS, Elgergawy AE, Elhalwagy AE. Evaluation of three-step procedure (Shehata's technique) as a conservative management for placenta accreta at a tertiary care hospital in Egypt. *J Gynecol Obstet Hum Reprod*. 2019;48(3):201-5. [DOI:10.1016/j.jogoh.2018.10.007] [PMID]
  5. Rasheedy R, Sammour H, Elkholy A, Fadel E. Agreement between transvaginal ultrasound and saline contrast sonohysterography in evaluation of cesarean scar defect. *J Gynecol Obstet Hum Reprod*. 2019;48(10):827-31. [DOI:10.1016/j.jogoh.2019.05.013] [PMID]
  6. Alalfy M, Osman OM, Salama S, Lasheen Y, Soliman M, Fikry M, et al. Evaluation of the Cesarean Scar Niche In Women With Secondary Infertility Undergoing ICSI Using 2D Sonohysterography Versus 3D Sonohysterography and Setting a Standard Criteria; Alalfy Simple Rules for Scar Assessment by Ultrasound To Prevent Health Problems for Women. *Int J Womens Health*. 2020;12(null):965-74. [DOI:10.2147/IJWH.S267691] [PMID] [PMCID]
  7. Savukyne E, Machtejeviene E, Paskauskas S, Ramoniene G, Nadisauskiene RJ. Transvaginal sonographic evaluation of cesarean section scar niche in pregnancy: a prospective longitudinal study. *Medicina*. 2021;57(10):1091. [PMCID] [DOI:10.3390/medicina57101091] [PMID]
  8. Rosa F, Perugin G, Schettini D, Romano N, Romeo S, Podestà R, et al. Imaging findings of cesarean delivery complications: cesarean scar disease and much more. *Insights Imaging*. 2019;10(1):98. [DOI:10.1186/s13244-019-0780-0] [PMID] [PMCID]
  9. Donnez O. Cesarean scar defects: management of an iatrogenic pathology whose prevalence has dramatically increased. *Fertil Steril*. 2020;113(4):704-16. [DOI:10.1016/j.fertnstert.2020.01.037] [PMID]
  10. Dicle O, Küçükler C, Pirnar T, Erata Y, Posaci C. Magnetic resonance imaging evaluation of incision healing after cesarean sections. *Eur Radiol*. 1997;7:31-4. [DOI:10.1007/s003300050103] [PMID]
  11. Ofili-Yebovi D, Ben-Nagi J, Sawyer E, Yazbek J, Lee C, Gonzalez J, Jurkovic D. Deficient lower-segment Cesarean section scars: prevalence and risk factors. *Ultrasound Obstet Gynecol*. 2008;31(1):72-7. [DOI:10.1002/uog.5200] [PMID]
  12. Tulandi T, Cohen A. Emerging Manifestations of Cesarean Scar Defect in Reproductive-aged Women. *J Minim Invasive Gynecol*. 2016;23(6):893-902. [DOI:10.1016/j.jmig.2016.06.020] [PMID]
  13. Roberge S, Boutin A, Chaillet N, Moore L, Jastrow N, Demers S, Bujold E. Systematic review of cesarean scar assessment in the nonpregnant state: imaging techniques and uterine scar defect. *Am J Perinatol*. 2012;465-72. [PMID] [DOI:10.1055/s-0032-1304829]
  14. Bij de Vaate AJM, van der Voet LF, Naji O, Witmer M, Veersema S, Brölmann HAM, et al. Prevalence, potential risk factors for development and symptoms related to the presence of uterine niches following Cesarean section: systematic review. *Ultrasound Obstet Gynecol*. 2014;43(4):372-82. [DOI:10.1002/uog.13199] [PMID]
  15. Antila-Långsjö RM, Mäenpää JU, Huhtala HS, Tomás EI, Staff SM. Cesarean scar defect: a prospective study on risk factors. *Am J Obstet Gynecol*. 2018;219(5):458.e1-.e8. [DOI:10.1016/j.ajog.2018.09.004] [PMID]
  16. Ajong AB, Kenfack B, Agbor VN, Njotang PN. Ruptured caesarean scar ectopic pregnancy: a diagnostic dilemma in a resource-limited setting. *BMC Res Notes*. 2018;11(1):292. [PMID] [DOI:10.1186/s13104-018-3389-3] [PMCID]
  17. Kremer TG, Ghiorzi IB, Dibi RP. Isthmocele: an overview of diagnosis and treatment. *Rev Assoc Med Bras*. 2019;65(5):714-21. [DOI:10.1590/1806-9282.65.5.714] [PMID]

#### How to Cite This Article:

K. Omar, M., S. Dawood, A., Ahmed Radwan, S., M. Ossman, A. Assessment of Cesarean Scar Following Conservative Management for Placenta Accreta Spectrum at a Tertiary Care Hospital in Egypt. *J Obstet Gynecol Cancer Res*. 2024;9(2):167-73.

Download citation:

[RIS](#) | [EndNote](#) | [Mendeley](#) | [BibTeX](#) |